



# Language and the Cerebellum: Structural Connectivity to the Eloquent Brain

Katie R. Jobson<sup>1</sup> , Linda J. Hoffman<sup>1</sup>, Athanasia Metoki<sup>2</sup> , Haroon Popal<sup>1</sup> , Anthony S. Dick<sup>3</sup>, Jamie Reilly<sup>1,4</sup>, and Ingrid R. Olson<sup>1</sup>

<sup>1</sup>Department of Psychology, Temple University, Philadelphia, Pennsylvania, USA

<sup>2</sup>Department of Neurology, Washington University in St. Louis, St. Louis, Missouri, USA

<sup>3</sup>Department of Psychology, Florida International University, Miami, Florida, USA

<sup>4</sup>Department of Speech and Language Sciences, Temple University, Philadelphia, Pennsylvania, USA

**Keywords:** cerebellum, diffusion imaging, frontal lobe, human connectome project, language, tractography, white matter

## ABSTRACT

Neurobiological models of receptive language have focused on the left-hemisphere perisylvian cortex with the assumption that the cerebellum supports peri-linguistic cognitive processes such as verbal working memory. The goal of this study was to identify language-sensitive regions of the cerebellum then map the structural connectivity profile of these regions. Functional imaging data and diffusion-weighted imaging data from the Human Connectome Project (HCP) were analyzed. We found that (a) working memory, motor activity, and language comprehension activated partially overlapping but mostly unique subregions of the cerebellum; (b) the linguistic portion of the cerebello-thalamo-cortical circuit was more extensive than the linguistic portion of the cortico-ponto-cerebellar tract; (c) there was a frontal-lobe bias in the connectivity from the cerebellum to the cerebrum; (d) there was some degree of specificity; and (e) for some cerebellar tracts, individual differences in picture identification ability covaried with fractional anisotropy metrics. These findings yield insights into the structural connectivity of the cerebellum as relates to the uniquely human process of language comprehension.

## INTRODUCTION

One of the most controversial issues in cognitive neuroscience today is whether the cerebellum deserves a seat at the table of the core language network. Neuromotor control of speech, which is important for both comprehension and production of language (Fischer & Zwaan, 2008), can be affected by cerebellar damage, with ataxic dysarthria being a common outcome of cerebellar damage (Spencer & Slocomb, 2007). However, there is growing evidence suggesting the cerebellum's involvement in language goes beyond its well-established role in the motor aspects of speech and comprehension (Mariën et al., 2014). The most compelling findings come from studies of individuals with damage to the posterior cerebellum and a disorder known as cerebellar cognitive affective syndrome. Individuals with this disorder have disruptions in many cognitive functions, including features of language (Schmahmann & Sherman, 1998). Prior work has found that individuals with this disorder often produce agrammatic language output (De Smet et al., 2007; Mariën et al., 2000; Silveri et al., 1994), with concurrent deficits in sentence comprehension (De Smet et al., 2007; Murdoch & Whelan, 2007; Silveri,

Citation: Jobson, K. R., Hoffman, L. J., Metoki, A., Popal, H., Dick, A. S., Reilly, J., & Olson, I. R. (2022). Language and the cerebellum: Structural connectivity to the eloquent brain. *Neurobiology of Language*. Advance publication. [https://doi.org/10.1162/nol\\_a\\_00085](https://doi.org/10.1162/nol_a_00085)

DOI: [https://doi.org/10.1162/nol\\_a\\_00085](https://doi.org/10.1162/nol_a_00085)

Supporting Information: [https://doi.org/10.1162/nol\\_a\\_00085](https://doi.org/10.1162/nol_a_00085)

Received: 13 April 2022  
Accepted: 10 October 2022

Competing Interests: The authors have declared that no competing interests exist.

Corresponding Author:  
Ingrid R. Olson  
[iolson@temple.edu](mailto:iolson@temple.edu)

Handling Editor:  
Julie Fiez

Copyright: © 2022  
Massachusetts Institute of Technology  
Published under a Creative Commons  
Attribution 4.0 International  
(CC BY 4.0) license

2021), anomia as defined by deficits in word generation (De Smet et al., 2007; Mariën et al., 2000), and diminished verbal fluency (Hoche et al., 2018; Silveri, 2021). Although linguistic and motoric deficits are often co-morbid in acquired cerebellar injuries, these two domains are also dissociable (Ahmadian et al., 2019). The cerebellum has, however, proven to be an enigmatic lesion model. For example, people with acquired cerebellar injuries tend to experience rapid recovery of speech and language functions, with frank symptoms only apparent during the acute phase in adults (Fabbro et al., 2004).

Neuroimaging studies have supplemented and extended patient-based case studies. Recent studies have reported that language comprehension activates Lobule IV, Crus I & II, and Lobule IX in the posterior cerebellum (Geva et al., 2021; Vias & Dick, 2017), with a rightward cerebellar bias, due to the fact that cortico-cerebellar-cortical connections are crossed (Bostan et al., 2013). What is the computational role of this region in language? Several hypotheses have been offered. One idea is that the cerebellum modulates timing and sequencing of language production and language perception (Fiez, 2016; Ivry & Keele, 1989; Leggio & Molinari, 2015; Mariën et al., 2014; Mariën & Borgatti, 2018; Molinari et al. 1997; Molinari, 2015; Salman, 2002; Schwartze & Kotz, 2016). Another hypothesis is that the cerebellum is involved in automatizing a range of behaviors, including language (Doyon et al., 1998; Fiez, 2016; Ramnani, 2014; Vicari et al., 2018; Yang et al., 2014). A final hypothesis is that the cerebellum's role in language is related to the more general role of the cerebellum in verbal working memory (Chen & Desmond, 2005; Desmond et al., 1997; Marvel & Desmond, 2010; Peterburs et al., 2021).

The comprehensive mapping of cortico-cerebellar connectivity can provide a framework upon which to understand function. More specifically, rather than understanding the role of the cerebellum in language more broadly, the mapping of the pathways that connect language-specific regions in the cerebellum and cerebral language regions may show some specificity. If this connectivity can be shown to be functionally specialized for particular linguistic subdomains, it may show more specifically how the cerebellum contributes to each linguistic subdomain. For more than a hundred years it has been recognized that certain white matter tracts play a key role in language (Dejerine & Dejerine-Klumpke, 1895, 1901; Mirailié, 1896). Modern diffusion-weighted imaging (DWI) methods have allowed investigators to identify structural networks in the cerebrum essential for language (Dick & Tremblay, 2012; Duffau, 2015; Krestel et al., 2013; Middlebrooks et al., 2017; Smits et al., 2014). Whether cerebral language networks are structurally connected with portions of the cerebellum activated in language tasks is not known. Although functional connectivity studies have shown correlated activity between linguistically sensitive cortex and regions of the posterior cerebellum (reviewed in Vias & Dick, 2017) this method is far removed from "ground truth" evidence provided by postmortem tract tracing. Indeed, findings from functional connectivity often disagree with findings from structural connectivity (for an example, see Metoki et al., 2021).

Findings from tract tracing have shown that cerebellar connectivity to and from the cerebrum is uniquely defined by two major pathways. The cortico-ponto-cerebellar pathway projects from the cerebral hemispheres with decussation at the pons terminating in the contralateral cerebellar cortex. In contrast, the cerebello-thalamo-cortical pathway begins in the cerebellum then crosses over to synapse on the contralateral thalamus, continuing on to different regions of the cerebral cortex. The dentate nucleus of the cerebellum retains a topographically ordered pattern of connectivity (Dum & Strick, 2003; Palesi et al., 2021; Steele et al., 2017). It is presumed that this connectivity remains orderly throughout the cerebello-thalamo-cortical and cortico-ponto-cerebellar pathway tracts.

**Tractography:**

The act of measuring white matter voxel-by-voxel using various methods, producing reconstructions of pathways.

The goal of this study is to use DWI to help disentangle the role of the cerebellum in language comprehension. DWI provides information about what brain regions are communicating with each other via a mathematical model of axonal connectivity. Information about axonal connectivity can be used to determine which facets of language are mediated by the cerebellum.

We used a tractography pipeline that we previously developed for studying the role of the cerebellum in theory of mind (Metoki et al., 2021). We applied this pipeline to language regions of interest (ROIs) in the cerebellum and cerebrum. Cerebellar language ROIs were derived from the sentence comprehension task in the Human Connectome Project (HCP) task-fMRI data set (Binder et al., 2011). Cerebral ROIs were chosen a priori based on the sentence comprehension literature (Barch et al., 2013; Binder et al., 2011; Booth et al., 2007; Fengler et al., 2016; Friederici, 2002; Friederici et al., 2003; Keller et al., 2001; Kieren & Buckner, 2009; Rogalsky et al., 2008). We focused on language comprehension, rather than overt language production, with the goal of reducing the potential impact of motor processing. Because language tends to be strongly left lateralized in the cerebrum (Frost et al., 1999; Mariën et al., 2001; Takaya et al., 2015) and the cerebellum has crossed structural connectivity with the cerebrum (Gonzalo-Ruiz & Leichnetz, 1990; Ito et al., 1986; Kelly & Strick, 2003), we performed lateralized tractography between language-sensitive ROIs in the right cerebellum to language-sensitive ROIs in the left cerebrum. Based on prior DWI work (Metoki et al., 2021) as well as monkey histology work (Glickstein et al., 1985; Schmahmann, 1996) we predicted that there would be significantly more fibers to linguistically sensitive frontal cerebral ROIs, like the left inferior frontal gyrus (IFG), as compared to linguistically sensitive ROIs in the temporal lobe.

## MATERIALS AND METHODS

### Data Set and Participants

All data used in this study are part of the HCP data set, specifically the WU-Minn HCP Consortium S900 Release (WU-Minn HCP Consortium, 2015). This data set is publicly available and accessible at <https://www.humanconnectome.org>. Only participants that completed all imaging sessions of interest (T1/T2, task fMRI), and DWI scans were included in this study. We restricted our population to only right-handed subjects using the Edinburgh Handedness questionnaire (Oldfield, 1971). We chose a random subset of 100 participants (50 females,  $M$  age = 27.89 yr,  $SD$  = 3.9 yr), as using a large sample size incurs a computational cost, given that probabilistic tractography is mathematically intensive. Unless otherwise stated, all significant results reported in this study were corrected for multiple comparisons using the false discovery rate correction (Benjamini & Hochberg, 1995).

### Overview of HCP Behavioral Protocol

While known for its neuroimaging data, the HCP protocol also includes several behavioral assessments conducted outside of the scanner. The NIH Toolbox for Assessment of Neurological and Behavioral function was of most interest to us, in particular their tasks related to language comprehension. The NIH Toolbox Picture Vocabulary Test, a measure of receptive language, was our dependent behavioral measure. This particular version of the task was adaptive, which allowed for more variation in the data (for additional detail see Gershon et al., 2014). Note that fMRI tasks are generally designed to produce strong blood oxygen level dependent (BOLD) signals but often have very little variance in the resultant behavioral outcomes. The HCP behavioral tasks used outside of the scanner elicited higher variance in the

**Diffusion imaging:**

An MRI scan that measures the diffusivity of water within the brain—this method allows us to approximate white matter pathways.

behavioral outcomes, making them potentially more sensitive for analyses of individual differences.

**Overview of HCP fMRI Protocol**

A detailed description of the HCP data acquisition and preprocessing pipelines can be found elsewhere (Barch et al., 2013; Glasser et al., 2013; Smith et al., 2013; Van Essen et al., 2012). Briefly, the HCP protocol includes acquisition of structural MRI, task-state fMRI, diffusion MRI, and extensive behavioral testing. The imaging data used in this article are the “minimally pre-processed” subjects included in the WU-Minn HCP Consortium S900 Release (WU-Minn HCP Consortium, 2015). This includes standard preprocessing using TOPUP, EDDY, and BED-POSTX. Details of imaging protocols, preprocessing pipelines, and in-scanner task protocols can be found in the Supporting Information, which can be found at [https://doi.org/10.1162/nol\\_a\\_00085](https://doi.org/10.1162/nol_a_00085).

Task-state fMRI encompasses seven major domains, three of which were used in this study: (1) working memory/cognitive control systems; (2) motor (visual, motion, somatosensory, and motor systems); and (3) language comprehension. The main task of interest was the language task (Binder et al., 2011). Participants in the language task listened to stories adapted from Aesop’s fables (ca. fourth century B.C.E./2012). Sentences were read aloud by a text-to-speech program to participants in the scanner. After listening to the stories, the participants were presented with a two-answer forced choice question about the contents of the story. The question was meant to probe understanding about the theme of the story, thus evoking activations related to comprehension (Binder et al., 2011). Participants selected one of the two answers by pushing a button. Specific details about the contents of the stories such as number of events, number of actors, mean sentence length, and duration are described in detail by Binder and colleagues (2011). The accompanying control task involved participants doing math problems. The design of this task was the same as the language task, with the same text-to-speech method used to present the stimuli. Rather than listening to a story, participants were read math problems aloud (“six times two equals..”). Participants were presented with a mathematical problem and were asked a two-answer forced choice question. The difficulty of the math task was increased after six correct responses and decreased in difficulty after one incorrect response. Descriptions of the working memory and motor tasks, used in the overlap and control analyses, are further described in the Supporting Information.

The results of the language fMRI task in the scanner did not yield enough variance to examine its potential relationship with our white matter pathways. Instead, we included participants’ performance on the NIH Toolbox Picture Vocabulary Test as our dependent behavioral measure.

**Regions of Interest**

We used two sets of ROIs for our analyses: one set in the cerebrum and one in the cerebellum. Because language is strongly lateralized, we limited our ROIs to the left cerebral hemisphere and to the right cerebellum. The set of cerebral ROIs were drawn from prior work on language. The cerebral ROIs included the following: angular gyrus (ANG; Fengler et al., 2016; Keller et al., 2001; Van Ettinger-Veenstra et al., 2016), dorsolateral prefrontal cortex (DLPFC; Keller et al., 2001; Kieren & Buckner, 2009), superior temporal gyrus (STG; Barch et al., 2013; Binder et al., 2011; Booth et al., 2007; Fengler et al., 2016; Friederici et al., 2003; Keller et al., 2001; Turken & Dronkers, 2011), middle temporal gyrus (MTG; Binder et al., 2011; Keller et al., 2001; Turken & Dronkers, 2011; Van Ettinger-Veenstra et al., 2016), inferior

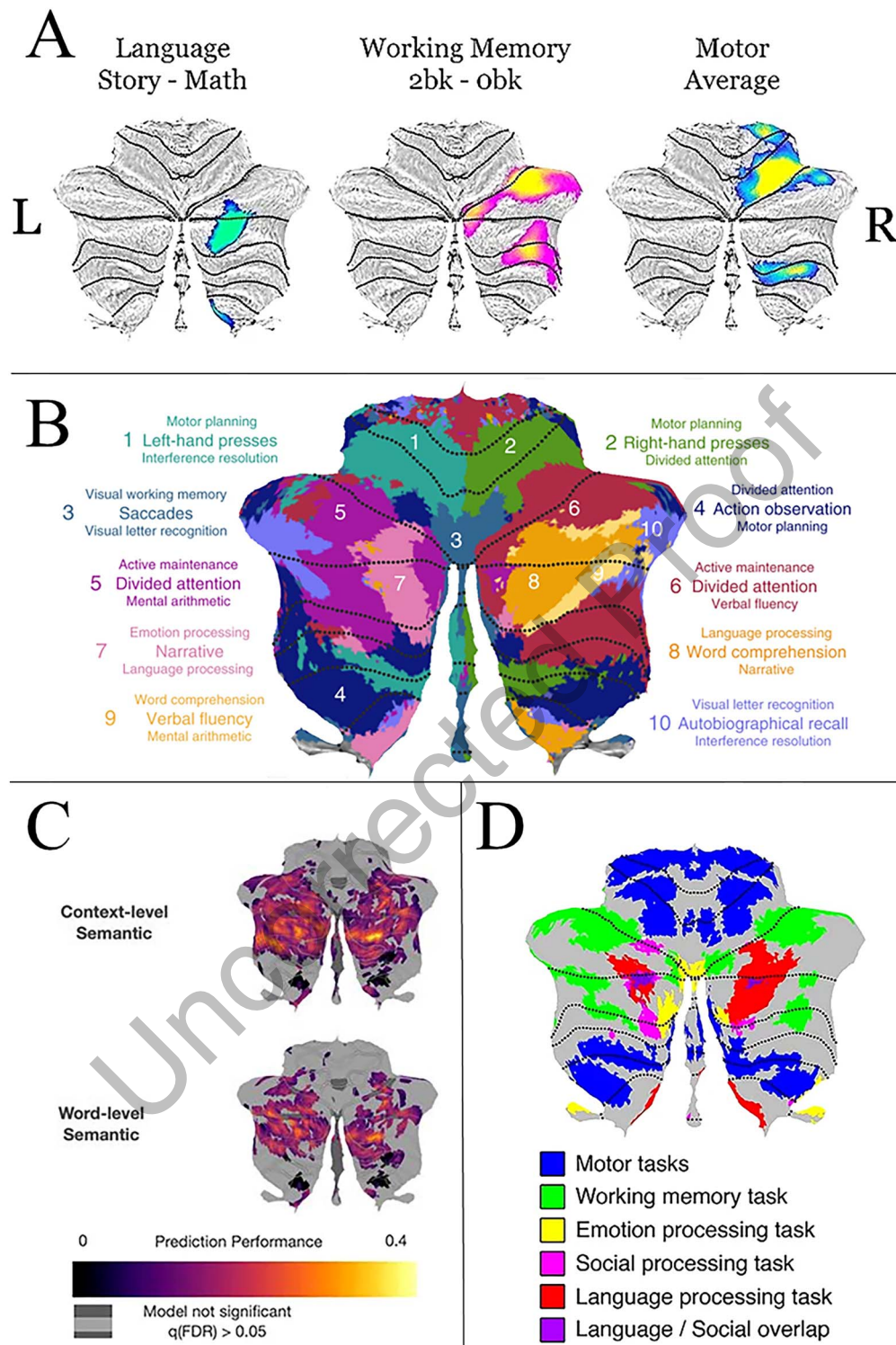
temporal gyrus (ITG; Ikuta et al., 2006), temporal pole (TP; Barch et al., 2013; Binder et al., 2011), IFG/Broca's area (Barch et al., 2013; Binder et al., 2011; Booth et al., 2007; Van Ettinger-Veenstra et al., 2016), and posterior superior portion of the temporal lobe (PST; Just et al., 1996; Mesulam et al., 2015). This area is often considered to be synonymous with Wernicke's area; however, because there is a lack of consensus regarding its location in the field (Tremblay & Dick, 2016), throughout this article we will refer to this area as the PST. Although other brain areas also support language, we focused on regions that have been consistently implicated in sentence comprehension. Coordinates for cerebral ROIs were taken from Neurosynth (<https://neurosynth.org/>; Yarkoni et al., 2011) by searching for the name of the region under "terms" and taking the voxel with the highest z-score using a cluster analysis. Using the term *superior posterior* produced an activation map closest to the agreed-upon anatomical location of Wernicke's area (Tremblay & Dick, 2016). Unfortunately, the highest z-scored voxel produced under the term *posterior superior* was too posterior for the aims of this study. Instead, we took the highest z-scored voxel that was also close enough to Heschl's gyrus as justification for using it to represent the PST. See Table A in the Supporting Information for exact MNI (Minnesota Neurological Institute) coordinates and accompanying z-scores for each ROI. Subsequently, each coordinate was then transformed into a 6 mm sphere using FSL software (Jenkinson et al., 2012), to be used in the analysis.

For the ROIs in the cerebellum, we used a different approach. Although several studies have attempted to functionally map the cerebellar cortex (Buckner et al., 2011; Diedrichsen & Zotow, 2015; Guell, Gabrieli, et al., 2018; Guell, Schmahmann, et al., 2018; King et al., 2019; Kieren & Buckner, 2009; Marek et al., 2018; Riedel et al., 2015), there is no consensus about functional boundaries within the cerebellum. Hence, it was impossible to employ the same approach we used with the predefined cerebral ROIs. Instead, we used a data-driven approach. Following the method used by Guell, Gabrieli, et al. (2018), we transformed FSL's level 2 individual cope files (results of within-subject fixed-effects grayordinate-based analyses that generate output files that index mean effects for an individual subject averaged across the two scan runs for a task) into Cohen's *d* group maps by first transforming the grayordinate. dscalar.nii files to NIfTI. We then used FSL commands `fslselectvols`, to extract the contrast of interest "story > math" for each individual, and `fslmerge`, `fslmaths -Tmean`, `-Tstd`, and `-div` to merge the individual contrast images, extract the mean and the standard deviation, and divide the two, ultimately getting group Cohen's *d* maps for the contrasts "story > math" (language), "2-back > 0-back" (working memory), and "average" (motor) based on a larger sample of 671 subjects. The HCP S900 Release provides level 3 group z-maps, but Cohen's *d* maps made it possible to observe the effect size of each task contrast rather than the significance of the BOLD signal change. A sample of 671 subjects ensures that a *d* value higher than 0.5 (Cohen, 1988) will be statistically significant even after correction for multiple comparisons ( $d = z/\sqrt{n}$ ,  $d > 0.5$  we have  $z > 12.95$  for  $N = 671$ ; analysis of 17,853 cerebellar voxels would require  $p < 0.000028$  after Bonferroni correction, and  $p < 0.000028$  is equivalent to  $z > 4.026$ ). Accordingly, we used FSL's cluster tool, the Cohen's *d* maps, and a threshold of 0.5 to extract clusters of activation for each task and local maxima within each cluster. After using a whole cerebellar mask to retain only the clusters and local maxima within the right cerebellum, clusters smaller than 100 mm<sup>3</sup> were further removed to omit very small clusters that were considered to be noninformative and would make a comprehensive description of the results too extensive (see Figure 1 for a visualization of the three functional tasks). The coordinates of the remainder local maxima from the "story > math" (language) contrast within the cerebellum were used to create two group cerebellar ROIs (spheres, 6 mm radius) in the right hemisphere. This resulted in two language cerebellar ROIs: right Crus I and right Lobule IX. The same

#### Local maxima:

In regard to fMRI data, this refers to the voxel that has the highest amount of activity in a brain region of interest.





**Figure 1.** Functional activation to language tasks in the cerebellum. (A) Functional activations from this study to three tasks (language, working memory, and motor) displayed on a flatmap of the cerebellum. Only activations within the right cerebellar hemisphere are displayed; (B) A figure from King et al. (2019) depicting cerebellar activations to a range of cognitive and motor tasks. Note that there is overlap between their language activations (labeled primarily as numbers 7 and 8) and our language activations in (A). (C) A figure from LeBel et al. (2021) investigating sentence-level and word-level semantic language processing. (D) A figure from Guell, Schmahmann et al. (2018) displaying cerebellar activations to a range of cognitive and motor tasks from the HCP data set.

method was used to extract the cerebellar motor and working memory cerebellar ROIs, which were used in overlap and control analyses. Seven working memory ROIs were created, also in the right cerebellar hemisphere. Four of the seven cerebellar working memory ROIs overlapped with each other, so they were removed from the analysis, leaving three working memory ROIs in the cerebellum. The remaining cerebellar working memory ROIs were primarily located in Lobule IV, Crus I, and Lobule VIIb.

#### Cluster Overlap and Euclidean Distances

Given that the HCP data set uses FNIRT (Andersson, 2010) registration to the MNI template, we calculated the percentage of overlap of each cerebellar cluster by using Diedrichsen's FNIRT MNI maximum probability map (Diedrichsen et al., 2009). Previous studies have already explored the overlap of several other tasks included in the HCP data set (Metoki et al., 2021). As a result, we only included three tasks in this analysis: language, working memory, and motor. We used FSL's atlasq tool to determine the percent overlap of each cerebellar cluster in the cerebellar lobes, hence determining the primary location of each cluster. The Sørensen–Dice coefficient, which is a statistic measuring the similarity of two samples (Dice, 1945; Sørensen, 1948), was then used to calculate the percentage of overlap between the functional clusters generated from all tasks and determine their similarity, and Euclidean distances were calculated to estimate the distances of local maxima within and between clusters. At the individual level, we thresholded z-scored  $\beta$ -weights of each subject's activation map for each task contrast to  $> 0$  to retain only increased activation during the tasks and then ran Wilcoxon signed-rank tests between each task pair to examine whether there was a statistical difference between them.

#### Diffusion Analyses

All diffusion analyses were completed on Temple University's High-Performance Computing Cluster, OwlsNest. Probabilistic tractography analyses were performed using FSL's probtrackx2 (probabilistic tracking with crossing fibres, Version 6.0.2; Behrens et al., 2003, 2007) in each subject's native space. Due to HCP preprocessing steps, this native space we refer to is the subjects' T1w space. After tractography, results were then transformed to MNI standard space using transformation matrices (see Supporting Information for more details). An ROI-to-ROI approach was used with cerebral and cerebellar ROIs used as seeds and targets to reconstruct each subject's cerebello-cerebral white matter connections. Fiber tracking was initialized in both directions separately (from seed to target and vice versa) and 5,000 streamlines were drawn from each voxel in each ROI. Tract length correction was also used, as cerebellar tracts are lengthy due to their polysynaptic nature, and length of a tract can introduce more false positives to the data (Jones, 2010). Tractographies were performed to delineate the cerebello-thalamo-cortical pathway, which projects from the cerebellar cortex to the deep cerebellar nuclei then crosses over to synapse on the contralateral thalamus, continuing on to different regions of the cerebral cortex (Middleton & Strick, 1997; Palesi et al., 2015; Schmahmann & Pandya, 1997) and the cortico-ponto-cerebellar pathway, which projects from the cerebral hemispheres to the pons, then to the contralateral cerebellar cortex (Palesi et al., 2017; Ramnani, 2006). For the cerebello-thalamo-cortical tractographies, a binarized mask of the superior cerebellar peduncle in MNI space from the Johns Hopkins University ICBM-DTI-81 white-matter labels atlas (Hua et al., 2008; Mori et al., 2005; Wakana et al., 2007) and left thalamus in MNI space from the Harvard-Oxford subcortical atlas (Desikan et al., 2006; Frazier et al., 2005; Goldstein et al., 2007; Makris et al., 2006) were used as waypoints respectively. The binarized contralateral cerebellar and cerebral hemispheres, lobes of non-interest,

and the opposing cerebellar peduncle were set as exclusion masks. All cerebral masks were created using the Harvard-Oxford cortical atlas (Desikan et al., 2006; Frazier et al., 2005; Goldstein et al., 2007; Makris et al., 2006). For example, cerebello-thalamo-cortical tractography between the right cerebellum and left DLPFC included the right superior cerebellar peduncle and left thalamus as waypoints. The exclusion mask was comprised of the left cerebellar hemisphere, right cerebral hemisphere, middle cerebellar peduncle, precentral gyrus, as well as the temporal, parietal, and occipital lobes. For the cortico-ponto-cerebellar pathway tractographies, a binarized mask of the middle cerebellar peduncle in MNI space from the same atlas was used as a waypoint. The contralateral cerebellar and cerebral hemispheres, right superior cerebellar peduncle, and lobes of non-interest were used as exclusion masks. For example, cortico-ponto-cerebellar pathway tractography between a left temporal lobe ROI and right cerebellar ROI would entail the middle cerebellar peduncle waypoint mask. The exclusion mask included the left cerebellar hemisphere, right cerebral hemisphere, right superior cerebellar peduncle, precentral gyrus, and frontal, parietal, and occipital lobes. Exact regions included in each exclusion mask can be found in Table B in the Supporting Information. The pons was not selected as an inclusion mask because of its absence from any standardized atlases. Despite not having the pons as an orthogonal waypoint in the cortico-ponto-cerebellar pathway tract, we did include the thalamus in the cerebello-thalamo-cortical reconstruction to follow previous literature (Palesi et al., 2015) and to ensure our tractography was as anatomically similar to the ground truth as possible. Our exclusion masks were comprehensive, as we had certain expectations as to where the tract would be traveling and terminating (Schilling et al., 2020). For cerebral ROIs in the frontal lobe, we knew that we were not interested in fibers that extended into other regions, such as the parietal or temporal lobes; therefore we incorporated them in the exclusion mask for that ROI. We also excluded the motor cortex with the knowledge that there are tracts from the cerebellum to the motor cortex. Exclusion of the motor cortex ensured our results were not due to connections between cerebral motor regions and our ROIs in the cerebellum.

Two metrics were extracted to be used as dependent measures in our analyses. Volume was extracted from the streamline density map using FSL's `fsstats` and normalized using intracranial volume (ICV; Voevodskaya et al., 2014). Intracranial volume was calculated using the method of Malone et al. (2015). This involves isolating the skull-stripped T1-weighted image provided by HCP in the same native space as the diffusion data and segmenting the brain using SPM12 into gray matter, white matter, and cerebral spinal fluid (in liters). The summed volumes of these tissue types yield the whole-brain intracranial volume, which when transformed into  $\text{mm}^3$  yields the metric for probabilistic tractography reported by FSL. Additionally, fractional anisotropy (FA) was extracted from respective cerebellar peduncles and included as a dependent variable. This was accomplished by taking whole-brain FA scalar data in native space (the result of the command `dtifit`, which is run on eddy-corrected data) and using each of the peduncles to mask the data. This produced FA maps exclusively within each peduncle. That data was then transformed into standard space, which allowed us to extract microstructural information of each tract within each peduncle. We chose to extract microstructural indices from only the peduncles following previous literature, as the peduncles are generally a good point in the tract to evaluate white matter cohesion (Jossinger et al., 2021; Taoka et al., 2007; Wang et al., 2003). Selecting only one region along the resulting tractography was expected to reduce some of the noise that would be introduced at the termination of the tract, which is a concern for such lengthy fiber pathways. This also allowed us to isolate the contribution of the cerebellar pathways in behavior, without picking up on cerebral white matter pathways (such as the arcuate fasciculus).



## RESULTS

### Functional Domains in the Cerebellum

We first examined whether there was overlap between language, working memory, and motor activations in the right cerebellum. We found that there was a significant difference in localizations for all three task pairs. Overall motor activations were localized to the anterior cerebellum (Lobules I–IV), with some activation in the posterior cerebellum (Lobules VIIB and VIIIA). Overall language activations were localized to Crus I/II and Lobule IX. Overall working memory activations were found in Crus I/II, Lobule VI, Lobule VIIb, and Lobule VIIa. The  $\beta$ -weights of each subject's activation map that were previously extracted, we performed Wilcoxon signed-rank tests for each task pair to examine whether there was a statistical difference between them. The language and motor activations had no overlap, while the language and working memory functional activations had minimal overlap (0.005%; see Table 1). After conducting the analyses on the overall activations from these tasks, the peak activation was extracted from the group activation maps and transformed into 6 mm spheres in FSL to be used in subsequent analyses.

### Cerebellar Structural Connections: Language–Language

Next, we asked whether language-sensitive regions in the cerebellum, which are poorly understood and have received little attention, are structurally connected to language-sensitive areas in the cerebrum that have been studied for over a century. We ran probabilistic tractography to reconstruct the cerebello-thalamo-cortical and cortico-ponto-cerebellar pathway white matter pathways between ROIs in the right cerebellum and left cerebral cortex. Volume was extracted for the cerebello-thalamo-cortical and cortico-ponto-cerebellar pathways and FA (microstructure) was extracted for the superior (cerebello-thalamo-cortical tracts) or middle (cortico-ponto-cerebellar tract) peduncles.

The average volume for tracts (before correction for intracranial volume) ranged from 74,714.32 mm to 240,083.92 mm. There were significant differences between the cerebello-thalamo-cortical and cortico-ponto-cerebellar pathways with lower volume in the cortico-ponto-cerebellar pathways (see Table 2 and Figure 2;  $W = 8,614$ ,  $p < 0.001$ ). For the cerebello-thalamo-cortical pathway, we examined whether there was a difference in the average volume between each cerebellar ROI seed (Crus I and Lobule IX). For this analysis, we intended to isolate the average volume when a tract was seeded in a cerebellar region to identify if one seed had a relatively greater volume of tracts being sent to the cerebrum. We accomplished this by taking each tract seeded in its respective cerebellar ROI to each of the eight cerebral targets (IFG, DLFPC, ANG, TP, STG, MTG, PST, ITG) and averaging the numbers. Using a paired Wilcoxon signed-rank test, we found no significant difference in tract volume

**Table 1.** The Sørensen–Dice coefficient (in percentages) between the three functional activations for the tasks of interest in the right cerebellar hemisphere.

fMRI task activation	Language	Working memory	Motor
Language			
Working memory	0.0051		
Motor	0	0.1507	

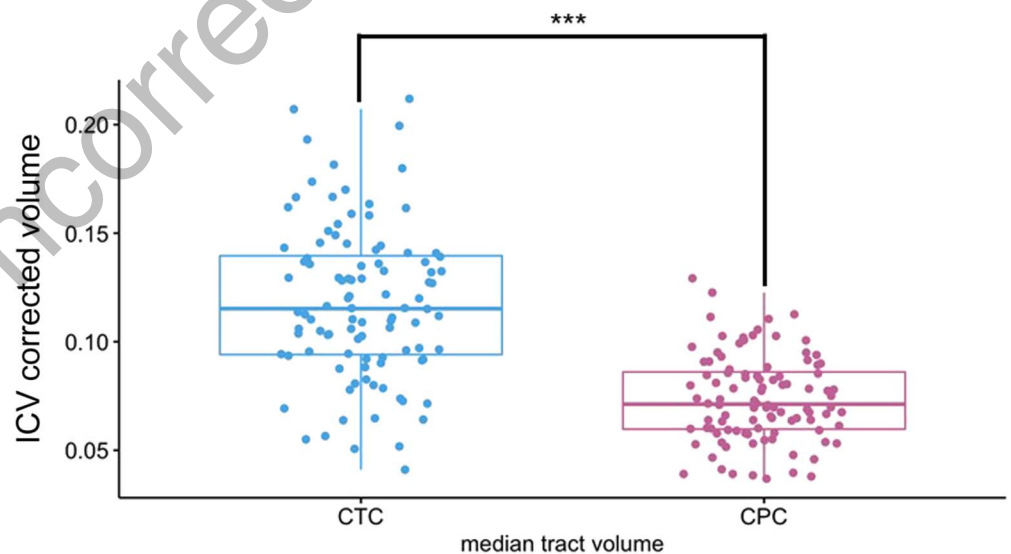
Note. All three tasks showed very little overlap. Representation of the activations is depicted in Figure 1.

**Table 2.** A summary comparison of the volumes and standard deviations for the cortico-ponto-cerebellar (CPC) and cerebello-thalamo-cortical (CTC) connections to language-related cortical regions.

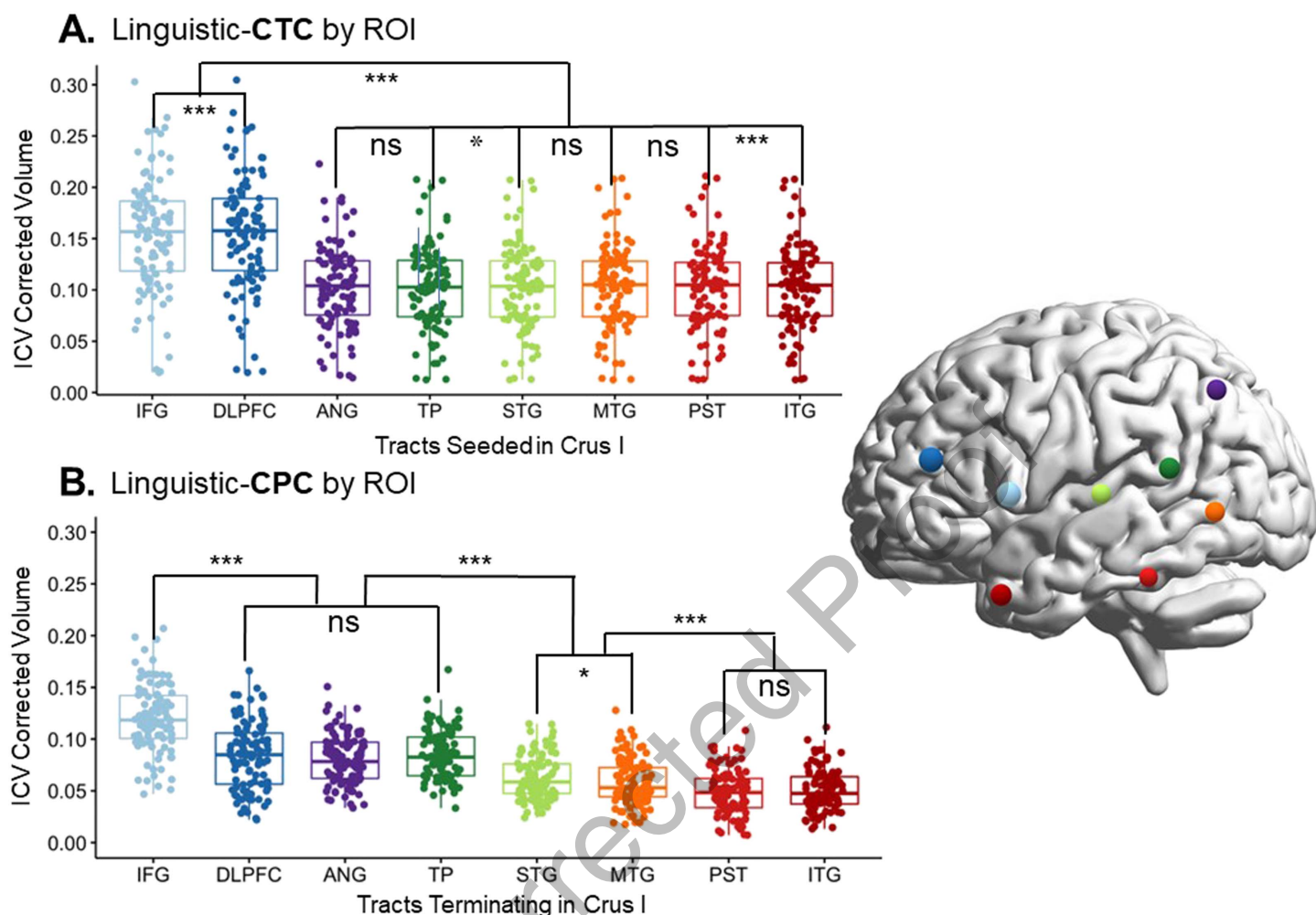
Language ROI	CTC (seeded in Crus I)				CPC (seeded in Crus I)			
	Uncorrected Vol.		ICV Corrected Vol.		Uncorrected Vol.		ICV Corrected Vol.	
	Mean	SD	Mean	SD	Mean	SD	Mean	SD
<i>STG</i>	150664.72	55440.85	0.10	0.04	91803.12	26480.96	0.06	0.02
<i>MTG</i>	150863.84	55557.13	0.10	0.04	85077.28	30491.50	0.05	0.02
<i>ITG</i>	150506.24	55179.80	0.10	0.04	74621.92	27725.44	0.05	0.02
<i>ANG</i>	150000.88	54587.71	0.10	0.04	117644.72	30662.77	0.08	0.02
<i>TP</i>	150073.92	55120.73	0.10	0.04	123634.80	28211.70	0.09	0.02
<i>IFG</i>	226984.88	74864.76	0.16	0.06	175971.60	41002.20	0.08	0.03
<i>DLPFC</i>	228344.00	75418.98	0.16	0.06	122568.64	45010.97	0.12	0.03
<i>PST</i>	151325.60	55894.72	0.10	0.04	71870.72	29796.13	0.05	0.02

Note. The cerebellar region of interest for all tracts is Crus I for the delineated descriptives. ICV = intracranial volume.

based on cerebellar seed. Paired Wilcoxon signed-rank tests were then used to look at differences in volume based on target cerebral ROIs for cerebello-thalamo-cortical pathways. We found that tracts terminating in frontal lobe ROIs (IFG and DLPFC) had significantly higher volumes than those of any tracts terminating in other lobe (see Figure 3A). There was no difference between the parietal and temporal lobe tract volumes, but we found some



**Figure 2.** Median volume of the linguistic portion of the cerebello-thalamo-cortico (CTC) and cortico-ponto-cerebellar (CPC) tracts. Each pathway was created by averaging the volume of all tracts across all eight cerebral regions of interest (ROIs), resulting in a single average volume per tract for each participant. For example, the CTC seeded in Crus I had tracts calculated for each of the right cerebral ROIs. All eight of those tract volumes were averaged to create the CTC plot shown in this figure. Note that the size of the ROIs was identical in both analyses. For this particular example, pathways seeded/terminated in Crus I. This was done for illustration purposes. Each dot represents a single participant; \*\*\* indicates  $p < 0.001$ .



**Figure 3.** Volume comparison between tracts. (A) Tract beginning in right Crus I and ending in different left-lateralized cerebral language targets. (B) Tracts projecting from cerebral language ROIs to the target in Crus I. For this particular example, pathways seeded/terminated in Crus I. This was done for illustration purposes. For further information about each individual pairwise comparison, see Table C in the Supporting Information. CTC = cerebello-thalamo-cortical pathway; CPC = cortico-ponto-cerebellar pathway; ICV = intracranial volume; IFG = inferior frontal gyrus/Broca's area; DLPFC = dorsolateral prefrontal cortex; ANG = angular gyrus; TP = temporal pole; STG = superior temporal gyrus; MTG = middle temporal gyrus; PST = posterior superior temporal lobe; ITG = inferior temporal gyrus. \*\*\* indicates  $p < 0.001$ , \*\* indicates  $p < 0.05$ ; ns = nonsignificant.

diversity among temporal lobe ROIs. We found a significant difference between MTG and PST ( $V = 1139$ ,  $p = 0.037$ ), ITG and PST ( $V = 880$ ,  $p < 0.001$ ), as well as between the TP and PST ( $V = 997$ ,  $p < 0.001$ ). There was also a significant difference between IFG and DLPFC volumes, with IFG having the greater volume between the two ( $V = 699$ ,  $p < 0.001$ ).

We found a different pattern of connection for the cortico-ponto-cerebellar pathway pathway (see Figure 3B). Again using paired Wilcoxon signed-rank tests, we found that there was still a statistically significant difference between the IFG and all other cerebral ROIs. Additionally, there were differences in volume in the temporal and parietal ROIs. Rather than the frontal ROIs being greater than the rest and all other tracts being equal to each other, we found that tracts from the ANG, STG, and TP seeds had higher volumes than in the cerebello-thalamo-cortical tract. The overall pattern was  $IFG > DLPFC \cong ANG \cong TP > STG \cong MTG > WER \cong ITG$

**Table 3.** A summary comparison of the volumes and standard deviations for subsections of the cortico-ponto-cerebellar (CPC) and cerebello-thalamo-cortical (CTC) connecting to working memory (WM) regions.

WM ROI	CTC (projecting to IFG)				CPC (seeded in IFG)			
	Uncorrected Vol.		ICV Corrected Vol.		Uncorrected Vol.		ICV Corrected Vol.	
	Mean	SD	Mean	SD	Mean	SD	Mean	SD
<i>Lobule IV</i>	173764.88	41627.86	0.09	0.04	138546.08	56472.37	0.12	0.03
<i>Crus I</i>	175658.40	41211.88	0.10	0.04	135630.24	61385.95	0.12	0.03
<i>Lobule VIIb</i>	174411.04	40735.06	0.14	0.05	200515.76	68625.34	0.12	0.03

Note. The CPC projections to WM regions in the cerebellum are seeded in the IFG, while in the CTC WM cerebellar regions are projecting to IFG. ROI = region of interest; IFG = inferior frontal gyrus; ICV = intracranial volume.

(with  $\cong$  signaling statistical equivalence). Overall for both tracts, the tracts whose cerebral ROIs were IFG/Broca's area had the highest volume (significant at  $p < 0.001$  in all pairwise comparisons; see Table C in the Supporting Information for full list of comparisons).

#### Cerebellar Structural Connections: Language–Working Memory

To examine the specificity of these white matter connections, we ran probabilistic tractography between the cerebellar working memory ROIs and cerebral language ROIs using the exact same waypoints and exclusion masks as in the language–language analyses. The language–language connections were then compared to the working memory–language connections. We examined the white matter tracts projecting to and from IFG, as this was our highest volume target and seed. Results showed that the white matter pathways from the working memory cerebellar ROIs to the language cerebral ROIs had significantly lower volumes for tracts going to IFG in the cerebello-thalamo-cortical tracts (all comparisons  $p < 0.001$ ; see Table C in the Supporting Information for all  $p$  values and effect sizes, and Table 3 for working memory tract means). Interestingly, in the cortico-ponto-cerebellar pathway tracts, there was one exception: working memory ROI in right Lobule VI was not significantly different in ICV corrected volume than language ROI right Crus I ( $W = 2,725$ ,  $p = 0.667$ ). These results suggest that there are specific structural connections between the linguistic cerebellar and cerebral areas, with the possibility that multiple regions of the cerebellum receive input from the same cerebral areas.

#### Cerebellar Microstructure: Brain-Behavior Correlations

Next, we investigated the microstructural properties of each tract to determine if we could find a relation between white matter and behavior. We used Spearman's rho to correlate FA extracted from the peduncles for each tract and the behavioral outcomes of the NIH Toolbox Picture Vocabulary Test from the HCP data set. Spearman's rho was used as some of our diffusion data from the cortico-ponto-cerebellar tract violated tests of normality (STG to Crus I:  $W = 0.964$ ,  $p = 0.024$ ; MTG to Crus I:  $W = 0.970$ ,  $p = 0.057$ ); STG to Lobule IX:  $W = 0.968$ ,  $p = 0.043$ ; MTG to Lobule IX:  $W = 0.977$ ,  $p = 0.058$ ). No significant correlations were found between microstructure of the cerebello-thalamo-cortical tract and picture naming ability. However, within the cortico-ponto-cerebellar tract there were several trending or significant correlations. For the tracts that had Crus I as the target, tracts seeded in: IFG ( $r = 0.23$ ,  $p = 0.058$ ), STG ( $r = 0.27$ ,  $p = 0.020$ ), and TP ( $r = 0.24$ ,  $p = 0.041$ ) were either trending or significant. For tracts with Lobule IX as the target, tracts seeded in: IFG ( $r = 0.24$ ,  $p = 0.044$ ), STG ( $r = 0.26$ ,  $p = 0.024$ ), and TP ( $r = 0.23$ ,  $p = 0.050$ ) were also significant (see Figure 5 in the Discussion section).



## DISCUSSION

In this study we mapped structural pathways between language-sensitive regions in the cerebellum and language-sensitive regions in the cerebral cortex. Our first step was to identify regions of the cerebellum sensitive to verbal comprehension and then to examine overlap with motor and working memory task activations. The regions activated to the sentence comprehension contrast were localized to Crus I/Crus II, and Lobule IX (see Figure 1) of the posterior cerebellum. The location of these activations is consistent with prior work that was conducted on different participants and using different stimuli (Geva et al., 2021; King et al., 2019). It should be noted that the activation in Lobule IX has been a controversial addition to the linguistic cerebellum. However, there is one piece of intriguing evidence linking it to receptive language: Geva and colleagues (2021) found that in their sample of six cerebellar lesion patients, damage to Lobule IX was the only lesion location that produced lasting deficits in sentence comprehension. Future research should examine this relationship more closely.

We found marginal overlap between the language and working memory tasks in Crus I, which is consistent with past literature (Marvel & Desmond, 2010). This overlap could be attributed to the nature of the language task. Participants listened to fables and later made judgments about the fables. This required them to remember the gist of five to nine sentences, a task that invokes verbal working memory. The fact that these fables also involve social scenarios explains our previous finding that the language task has nearly 50% overlap with activations from the theory of mind task (Metoki et al., 2021). There is a sizable literature linking portions of the cerebellum to normal and abnormal social cognition as observed in autism spectrum disorder (Stoodley & Tsai, 2021; Van Overwalle et al., 2021). Whether language tasks that are less social and have lower working memory loads (e.g., single word processing) would show overlap with language activations in the cerebellum is unknown. In contrast, there was no overlap between the language comprehension task and the motor task.

One explanation of the social and language overlap could be derived from the social sequencing hypothesis (Heleven et al., 2021; Van Overwalle et al., 2019; Van Overwalle et al., 2021). This hypothesis states that the cerebellum is involved in the prediction of social interaction by forming internal models (a representation of the predicted world based on previous experiences) about how sequential social events should unfold. The cerebellum uses associative information to identify what may come next in a sequence of events, such as another person's reaction or response. This relates to language because language is inherently social. Not only do we use it to relay information to other individuals, but the content of what we are relaying is often social. One study reported stronger activations in the cerebellum to social as compared to nonsocial sentences (Pu et al., 2020), adding credence to this idea. While the focus of our study was to parse receptive language and working memory, future work will need to be done to parse language and social cognition in the cerebellum.

The observed overlap between language and working memory led us to conduct a distance analysis. This showed that each cluster had distinct local maxima. We also analyzed the  $\beta$ -weights for each task at the individual level and found that all task pairs have a significantly different localization of activation. Overall, our results provide support for the hypothesis that the cerebellum contains domain-specific mapping of cognitive functions including language comprehension.

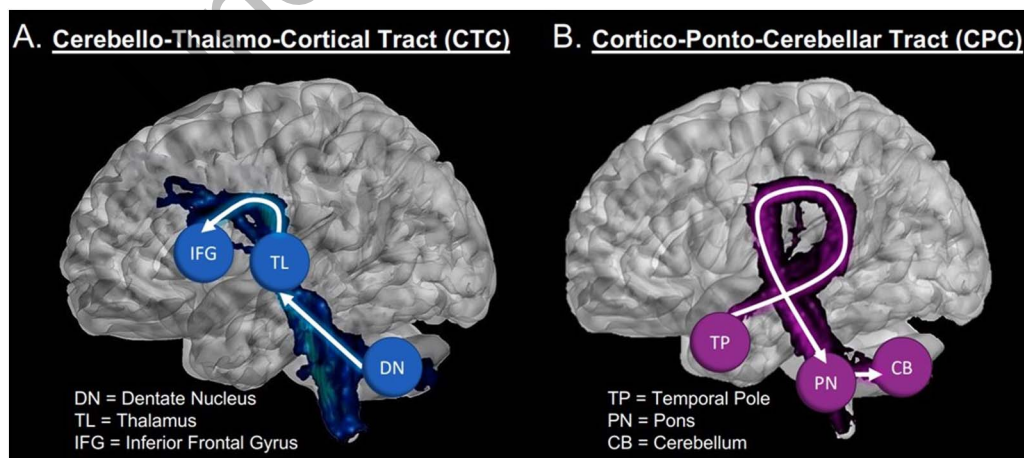
If these cerebellar regions truly play a role in language, they should be structurally connected to regions involved in language in the cerebrum. Histology methods in macaques have revealed an extensive network of fiber paths between the anterior cerebellum and nearly all nonmotor regions of the frontal lobe (Clower et al., 2005; Dum & Strick, 2003; Ito, 1984; Kelly

& Strick, 2003; Leiner et al., 1993; Middleton & Strick, 1997; Schmahmann & Pandya, 1997). In regards to the parietal lobe, gold-standard histology studies have found connections between the cerebellum and BA 5 and 7 in the macaque parietal lobe (Clower et al., 2005; Glickstein et al., 1985). Other histology studies in macaques have reported the existence of structural connections between the superior temporal lobe (e.g. the length of the STG, excepting A1, as well as the depths of the superior temporal sulcus), with the cerebellum (Schmahmann & Pandya, 1991). However, there are few to no connections between most of the MTG and ITG and the cerebellum (Schmahmann & Pandya, 1991). Thus, histological findings in macaques predict that we should find strong structural connectivity between the cerebellum and language ROIs in the frontal lobe and superior temporal lobe, but weaker structural connections between inferior parietal lobe and inferior temporal lobe ROIs and the cerebellum. This prediction must be tempered by the fact that language is a uniquely human trait, and changes have occurred in the human temporal and inferior parietal lobes through the evolution of language.

The results of our probabilistic tractography analysis partially confirmed the above predictions. First, we found that the volume of the language-specific cerebello-thalamo-cortical pathway was greater than the volume of the language-specific cortico-ponto-cerebellar pathway. This was not entirely unexpected as previous research found this bias when looking at the social portions of the cerebello-thalamo-cortical and cortico-ponto-cerebellar tracts (Metoki et al., 2021). Interpretation of this bias awaits further investigation.

Second, we found that in the cerebello-thalamo-cortical pathway, frontal lobe ROIs captured the majority of the projections from the cerebellum (IFG followed by the DLPFC; see Figure 3 and Figure 4). There was some elevated connectivity to the PST compared to other temporal lobe ROIs, but nothing compared to the volume of the pathways projecting to the frontal lobe, as was expected based on previous literature (Palesi et al., 2015).

However, the cortico-ponto-cerebellar pathway showed a different, more complex pattern of connectivity. While IFG still held the highest number of connections to the cerebellum, DLPFC, ANG, STG, and TP had elevated connectivity compared to other temporal lobe ROIs. The ANG and TP structural connections captured on average the same amount of volume as the DLPFC. The results involving the ANG and STG are not surprising, based on our review



**Figure 4.** Visualization of the cerebello-thalamo-cortical and cortico-ponto-cerebellar tracts. (A) The CTC tract running from Crus I of the cerebellum to inferior frontal gyrus (blue sphere). (B) The portion of the CPC tract, running from the temporal pole (red sphere) to cerebellar Crus I. Visualizations using 3D slicer (Fedorov et al., 2012; Kikinis et al., 2014).

of the tract tracing and histology literature (Ramnani, 2012; Schmahmann & Pandya, 1991). However, finding elevated volume in the projections coming from the TP were somewhat unexpected. There is one study in macaques showing that the temporal polar section of the superior temporal sulcus (TPO1) sends projections to the pons (Schmahmann, 1996), and likely continues onward into the cerebellum. However, we are not aware of any other ground truth studies.

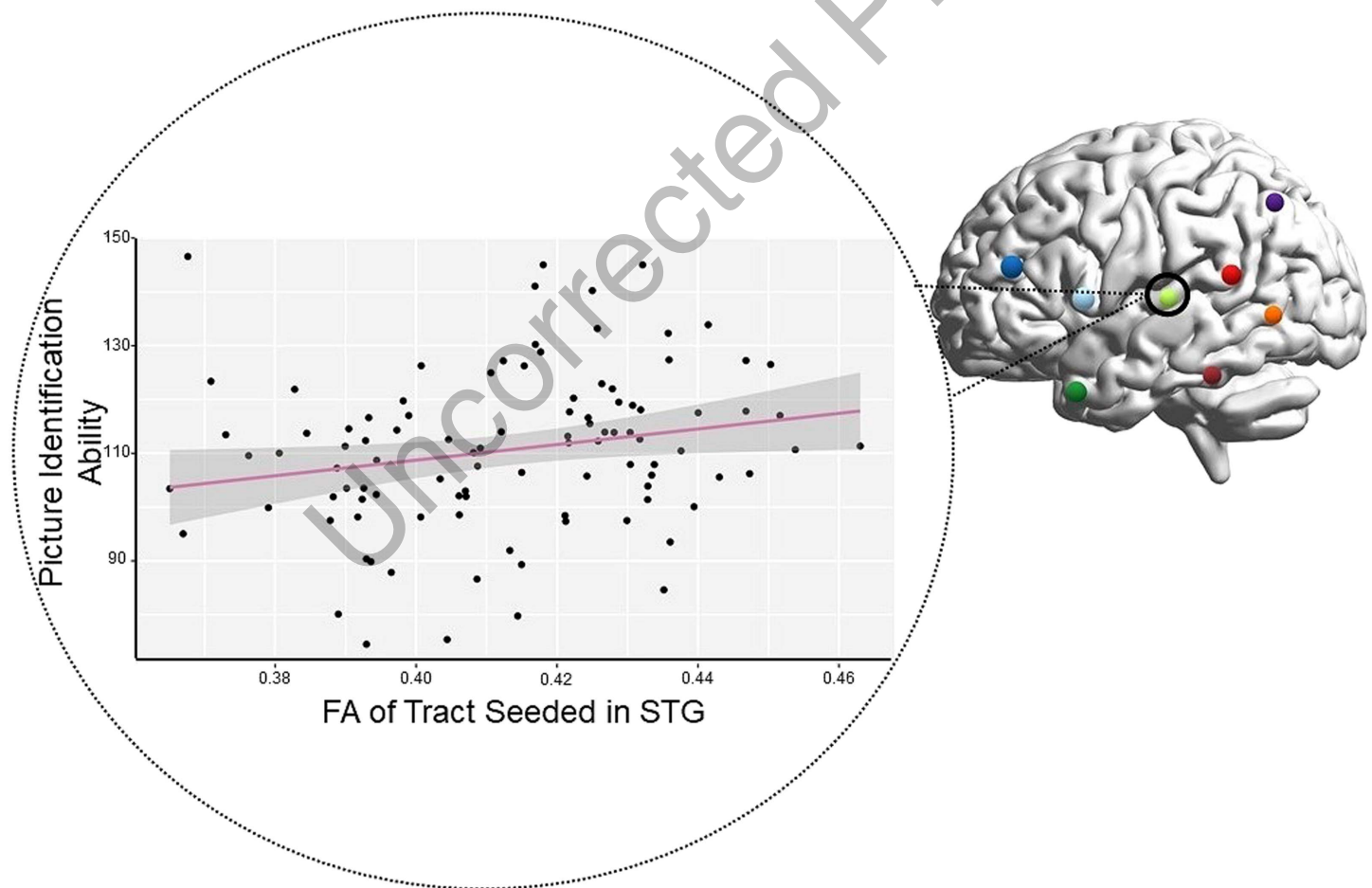
These results provide new insight on the “closed-loop” nature of cerebellum-to-cerebrum connections. Computational models describing the cerebellum’s functional contribution to motor processes have described a closed loop system in which motor regions in the cerebrum are connected to specific regions within the cerebellum, which in turn are connected to the same regions back in the cerebrum (Ito, 2008; Kawato & Gomi, 1992; Wolpert et al., 1998). Evidence of closed-loop cerebello-cerebral connections that would be critical for nonmotor processes have also been found (Palesi et al., 2017; Salmi et al., 2010; Strick et al., 2009), including closed-loops between the posterior cerebellum and the DLPFC (Kelly & Strick, 2003). However, as noted by Moberget and Ivry (2016, p. 12), “... a close examination of the primate data suggests that [closed loops] may not always be the case.” The asymmetry between the cerebello-thalamo-cortical and cortico-ponto-cerebellar pathway in our functionally defined ROIs suggest that multiple regions across the cerebral cortex may be providing input into a specific region of the cerebellum, which then outputs to a subset of those input regions. This finding highlights that the closed-loop nature of cerebellar connectivity may be more in line with a network modulation function—a many-to-one—rather than a single region-to-region, or one-to-one, modulation. Individual regions of the cerebellum would be well suited to receive inputs from a diverse set of brain regions, as cerebellum “microcomplexes,” thought to be the computational building blocks of the cerebellum, include an initial layer of cells that are well suited for high-dimensional inputs (Hull, 2020; Raymond & Medina, 2018).

To date, only a small number of studies have examined the cerebello-thalamo-cortical and cortico-ponto-cerebellar pathways in vivo (Jissendi et al., 2008; Karavasilis et al., 2019; Keser et al., 2015; Sokolov et al., 2014). This is likely due to the technical challenges present in doing tractography along a long, polysynaptic pathway that has crossovers and sharp turns. Thus most of the existing literature has simply looked at white matter within the cerebellum (e.g., the peduncles) rather than between the cerebellum and cerebrum. Our study is unique in that we carefully measured the linguistically relevant portion of the ouroboros loop in a large sample with excellent data quality.

Previous studies that reconstructed cerebello-thalamo-cortical and cortico-ponto-cerebellar pathways relied solely upon diffusion *tensor* imaging, which has had notable issues with crossing fibers (Lee et al., 2015). Crossing fibers are in abundance in the brainstem and within these tracts of interest (Ford et al., 2013). Our tractography has improved upon this with the use of the ball-and-stick model, which is better at resolving crossing fibers (Behrens et al., 2007). We modeled our methods after Palesi et al. (2017), who found evidence of projections of the cortico-ponto-cerebellar pathway originating from the temporal lobe with constrained spherical deconvolution. This method also has a better ability to solve for crossing fibers (Daducci et al., 2014; Tournier et al., 2008; Tournier et al., 2012). Palesi and colleagues’ analysis of all projections from association cortices showed that the temporal lobe sends projects to the cerebellum via the cortico-ponto-cerebellar pathway, even though it may not receive projections from the cerebello-thalamo-cortical. Schmahmann and Pandya (1991) also observed projections from the superior temporal sulcus to the cortico-ponto-cerebellar pathway in rhesus monkeys, so the results are not completely unfounded. It is possible these findings may be the result

of the software and not true projections found in the human brain, but converging evidence across multiple methodologies may suggest some shared truth.

In an exploratory analysis of DWI microstructure data, we found that individual differences in FA values in the cortico-ponto-cerebellar pathway correlated with receptive vocabulary ability. In other words, individuals with higher FA in the middle cerebellar peduncle of the cortico-ponto-cerebellar tract had better ability to identify a picture that matched a word with which they were presented. Note that all tracts projecting from regions of the temporal lobe, except for PST, had weak to moderate positive correlations with the receptive language. This suggests that individuals who have faster and more efficient transmission of auditory-linguistic information to the cerebellum perform better on single-word comprehension tasks (Figure 5). This is reflected in our findings with the TP and the STG. The correlation of the MTG ROI may be a little less straightforward. Some evidence has shown that the posterior MTG is involved in semantic control (Davey et al., 2015), while others have postulated that it could be involved in some form of integration between lobes (Turken & Dronkers, 2011). In addition, IFG also showed weak to moderate positive correlation with the task, which makes sense with its role in lexical and semantic processing (Dapretto & Bookheimer, 1999; Friederici et al., 2000).



**Figure 5.** Significant brain-behavior correlation: single-word comprehension performance correlated with fractional anisotropy (FA) of tract connecting the left superior temporal gyrus (STG) to the right cerebellum. Tracts seeded in the inferior frontal gyrus and temporal pole were also significant. Each colored sphere on the brain represents a cortical region of interest. Each black dot on the graph represents a single participant.



How selective are these findings? Our results show that there is some domain-specific connectivity to the cerebrum, even within large regions such as Crus I. Tracts from working memory ROIs in the cerebellum to language ROIs in the cerebrum were volumetrically smaller than the language–language tracts. This occurred even when the cerebellar ROIs from the different tasks were in the same lobule of the cerebellum. Some specificity was lost in the cortico-ponto-cerebellar tract (with fibers projecting to regions derived from the working memory task). Tracts seeded in IFG and projecting to working memory cerebellar regions Crus I were not significantly different in volume from the tracts projecting to the language ROI (also located in Crus I). The longer tracts get, the less accurate they are, so this result may just be due to the fact that the ROIs we had were located in the same lobule of the cerebellum. The specificity that these white matter tracts hold cannot be completely resolved without a more in-depth knowledge of what these pathways truly look like in humans. In addition, our findings help localize what type of cerebellar damage should cause language comprehension deficits: lesions to right Crus I or Lobule IX, as well as to the polysynaptic fiber paths connecting these regions to the cerebrum. Individuals with lesions that preserve these regions are not expected to exhibit any language comprehension deficits.

#### Limitations and Future Directions

First, the task set included in the HCP data set is limited, which limited the cerebellar seed regions used in our tractography analysis. Future studies should test the limits of our findings by employing a range of language production and reception tasks involving lower- and higher-level processing, mapping the functional ROIs, and conducting tractography. Second, diffusion MRI tractography has been criticized for having a high rate of false positives (Maier-Hein et al., 2017; Reveley et al., 2015; Thomas et al., 2014). The best solution to this problem is to conduct histology-guided tractography analyses followed by replication in independent samples. Third, the relationship between structural connectivity, as described here, and functional connectivity, as reported in many prior studies (reviewed in Vias & Dick, 2017) in regards to the linguistic cerebellum needs to be investigated in a larger-scale study. Last, like all neuroimaging analyses, results can depend on various factors including, for example, the selection of ROIs, waypoints, thresholding, and software choices. Every analytical decision made in this study was based on prior work exploring similar pathways (Metoki et al., 2021) with a small number of updates based on our understanding of best practices in diffusion imaging. However we are cognizant that diffusion imaging methods are relatively young, and standards are in flux. We hope that future investigators attempt replications of our work and that our findings are robust to different choices made in analytical parameters.

Future directions include the investigation of the specificity of the mentalizing and language cerebellar pathways. While it was shown that there was little functional overlap in the cerebellum between the language and working memory tasks, this was not the same for the language and mentalizing tasks. In order to further identify whether the language-specific pathways are truly language-specific, further research must be done between the language and mentalizing tasks in regards to diffusion tractography.

#### Conclusions

This neuroimaging study investigated the structural connectivity between language cerebellar and cerebral areas. We found projections from the cerebellum to language regions of the frontal lobe. There was also evidence of input to the cerebellum from other regions of the cerebrum, such as the ANG and the TP portion of the superior temporal sulcus. These findings

suggest that regions of the posterior cerebellum play a key role in language comprehension. We also found that these white matter tracts were, at least in part, specific to language-sensitive areas of the cerebellum and cerebrum.

#### ACKNOWLEDGMENTS

We would like to thank Angela Piecyk, Marah Dormuth, Sarah Johnson, Giovanna Arantes De Oliveira Campos, and Jason Konadu for their work as research assistants on this project. We would also like to thank Huiling Peng for assistance with tractography. Last, we would like to thank three anonymous reviewers for their helpful commentary.

This research includes calculations carried out on HPC resources supported in part by the National Science Foundation through major research instrumentation grant number 1625061 and by the US Army Research Laboratory under contract number W911NF-16-2-0189. The content is solely the responsibility of the authors and does not necessarily represent the official views of the National Institute of Mental Health or the National Institutes of Health.

#### FUNDING INFORMATION

Ingrid R. Olson, National Institutes of Health (<https://dx.doi.org/10.13039/1000000002>), Award ID: R21 HD098509. Ingrid R. Olson, National Institutes of Health (<https://dx.doi.org/10.13039/1000000002>), Award ID: R01 NICHD. Ingrid R. Olson, National Institute of Child Health and Human Development ([institution doi]), Award ID: R01HD099165. Ingrid R. Olson, National Institute of Mental Health (<https://dx.doi.org/10.13039/1000000025>), Award ID: MH091113.

#### AUTHOR CONTRIBUTIONS

**Katie R. Jobson:** Conceptualization: Lead; Data curation: Lead; Formal analysis: Lead; Methodology: Lead; Software: Lead; Validation: Lead; Visualization: Lead; Writing—original draft: Lead; Writing—review & editing: Supporting. **Linda J. Hoffman:** Formal analysis: Equal; Methodology: Supporting; Validation: Supporting; Writing—original draft: Supporting; Writing—review & editing: Equal. **Athanasia Metoki:** Formal analysis: Supporting; Methodology: Supporting; Writing—original draft: Equal; Writing—review & editing: Equal. **Haroon Popal:** Conceptualization: Supporting; Writing—original draft: Supporting; Writing—review & editing: Equal. **Anthony S. Dick:** Methodology: Supporting; Writing—review & editing: Equal. **Jamie Reilly:** Conceptualization: Supporting; Methodology: Supporting; Writing—review & editing: Equal. **Ingrid R. Olson:** Conceptualization: Equal; Formal analysis: Supporting; Funding acquisition: Lead; Resources: Lead; Supervision: Equal; Writing—original draft: Equal; Writing—review & editing: Equal.

### Q3 REFERENCES

- Aesop. (2012). *Fables* (J. R. Long, Comp.). Aesop's Fables online collection. <https://aesopfables.com>
- Ahmadian, N., van Baarsen, K., van Zandvoort, M., & Robe, P. A. (2019). The cerebellar cognitive affective syndrome—A meta-analysis. *Cerebellum*, 18(5), 941–950. <https://doi.org/10.1007/s12311-019-01060-2>, PubMed: 31392563
- Andersson, J. L. R., Jenkinson, M., & Smith, S. (2007). *Non-linear registration, aka spatial normalisation* (FMRIB Technical Report TR07JA2). FMRIB Centre. Oxford, UK.
- Barch, D. M., Burgess, G. C., Harms, M. P., Petersen, S. E., Schlaggar, B. L., Corbetta, M., Glasser, M. F., Curtiss, S., Dixit, S., Feldt, C., Nolan, D., Bryant, E., Hartley, T., Footer, O., Bjork, J. M., Poldrack, R., Smith, S., Johansen-Berg, H., Snyder, A. Z., ... WU-Minn HCP Consortium. (2013). Function in the human connectome: Task-fMRI and individual differences in behavior. *NeuroImage*, 80, 169–189. <https://doi.org/10.1016/j.neuroimage.2013.05.033>, PubMed: 23684877
- Behrens, T. E. J., Johansen-Berg, H., Jbabdi, S., Rushworth, M. F. S., & Woolrich, M. W. (2007). Probabilistic diffusion tractography with multiple fibre orientations: What can we gain? *NeuroImage*, 34(1), 144–155. <https://doi.org/10.1016/j.neuroimage.2006.09.018>, PubMed: 17070705

- Behrens, T. E. J., Woolrich, M. W., Jenkinson, M., Johansen-Berg, H., Nunes, R. G., Clare, S., Matthews, P. M., Brady, J. M., & Smith, S. M. (2003). Characterization and propagation of uncertainty in diffusion-weighted MR imaging. *Magnetic Resonance in Medicine*, *50*(5), 1077–1088. <https://doi.org/10.1002/mrm.10609>, PubMed: 14587019
- Benjamini, Y., & Hochberg, Y. (1995). Controlling the false discovery rate: A practical and powerful approach to multiple testing. *Journal of the Royal Statistical Society: Series B (Methodological)*, *57*(1), 289–300. <https://doi.org/10.1111/j.2517-6161.1995.tb02031.x>
- Binder, J. R., Gross, W. L., Allendorfer, J. B., Bonilha, L., Chapin, J., Edwards, J. C., Grabowski, T. J., Langfitt, J. T., Loring, D. W., Lowe, M. J., Koenig, K., Morgan, P. S., Ojemann, J. G., Rorden, C., Szaflarski, J. P., Tivarus, M. E., & Weaver, K. E. (2011). Mapping anterior temporal lobe language areas with fMRI: A multi-center normative study. *NeuroImage*, *54*(2), 1465–1475. <https://doi.org/10.1016/j.neuroimage.2010.09.048>, PubMed: 20884358
- Booth, J. R., Wood, L., Lu, D., Houk, J. C., & Bitan, T. (2007). The role of the basal ganglia and cerebellum in language processing. *Brain Research*, *1133*(1), 136–144. <https://doi.org/10.1016/j.brainres.2006.11.074>, PubMed: 17189619
- Bostan, A. C., Dum, R. P., & Strick, P. L. (2013). Cerebellar networks with the cerebral cortex and basal ganglia. *Trends in Cognitive Sciences*, *17*(5), 241–254. <https://doi.org/10.1016/j.tics.2013.03.003>, PubMed: 23579055
- Brodal, P., & Bjaalie, J. G. (1997). Salient anatomic features of the cortico-ponto-cerebellar pathway. *Progressive Brain Research*, *114*, 227–250. [https://doi.org/10.1016/S0079-6123\(08\)63367-1](https://doi.org/10.1016/S0079-6123(08)63367-1)
- Buckner, R. L., Krienen, F. M., Castellanos, A., Diaz, J. C., & Yeo, B. T. T. (2011). The organization of the human cerebellum estimated by intrinsic functional connectivity. *Journal of Neurophysiology*, *106*(5), 2322–2345. <https://doi.org/10.1152/jn.00339.2011>, PubMed: 21795627
- Buckner, R. L., Krienen, F. M., & Yeo, B. T. T. (2013). Opportunities and limitations of intrinsic functional connectivity MRI. *Nature Neuroscience*, *16*(7), 832–837. <https://doi.org/10.1038/nn.3423>, PubMed: 23799476
- Caplan, D., & Waters, G. (1999). Verbal working memory and sentence comprehension. *Behavioral and Brain Sciences*, *22*(1), 77–94. <https://doi.org/10.1017/S0140525X99001788>, PubMed: 11301522
- Chen, S. H., & Desmond, J. E. (2005). Cerebrocerebellar networks during articulatory rehearsal and verbal working memory tasks. *NeuroImage*, *24*(2), 332–338. <https://doi.org/10.1016/j.neuroimage.2004.08.032>, PubMed: 15627576
- Clower, D. M., Dum, R. P., & Strick, P. L. (2005). Basal ganglia and cerebellar inputs to AIP. *Cerebral Cortex*, *15*(7), 913–920. <https://doi.org/10.1093/cercor/bhh190>, PubMed: 15459083
- Cohen, J. (1988). *Statistical power analysis for the behavioral sciences* (2nd ed.). Lawrence Erlbaum.
- Daducci, A., Canales-Rodríguez, E. J., Descoteaux, M., Garyfallidis, E., Gur, Y., Lin, Y.-C., Mani, M., Merlet, S., Paquette, M., Ramirez-Manzanares, A., Reisert, M., Reis Rodrigues, P., Sepelband, F., Caruyer, E., Choupan, J., Deriche, R., Jacob, M., Menegaz, G., Prčkovska, V., ... Thiran, J.-P. (2014). Quantitative comparison of reconstruction methods for intra-voxel fiber recovery from diffusion MRI. *IEEE Transactions on Medical Imaging*, *33*(2), 384–399. <https://doi.org/10.1109/TMI.2013.2285500>, PubMed: 24132007
- Dapretto, M., & Bookheimer, S. Y. (1999). Form and content: Dissociating syntax and semantics in sentence comprehension. *Neuron*, *24*(2), 427–432. [https://doi.org/10.1016/S0896-6273\(00\)80855-7](https://doi.org/10.1016/S0896-6273(00)80855-7), PubMed: 10571235
- Davey, J., Cornelissen, P. L., Thompson, H. E., Sonkusare, S., Hallam, G., Smallwood, J., & Jefferies, E. (2015). Automatic and controlled semantic retrieval: TMS reveals distinct contributions of posterior middle temporal gyrus and angular gyrus. *Journal of Neuroscience*, *35*(46), 15230–15239. <https://doi.org/10.1523/JNEUROSCI.4705-14.2015>, PubMed: 26586812
- Dejerine, J., & Dejerine-Klumpke, A. M. K. (1895). *Anatomie des centres nerveux*. Rueff et Cie.
- Dejerine, J., & Dejerine-Klumpke, A. M. K. (1901). *Anatomie des centres nerveux*. Rueff et Cie.
- Desikan, R. S., Ségonne, F., Fischl, B., Quinn, B. T., Dickerson, B. C., Blacker, D., Buckner, R. L., Dale, A. M., Maguire, R. P., Hyman, B. T., Albert, M. S., & Killiany, R. J. (2006). An automated labeling system for subdividing the human cerebral cortex on MRI scans into gyral based regions of interest. *NeuroImage*, *31*(3), 968–80. <https://doi.org/10.1016/j.neuroimage.2006.01.021>, PubMed: 16530430
- De Smet, H. J., Baillieux, H., De Deyn, P. P., Mariën, P., & Paquier, P. (2007). The cerebellum and language: The story so far. *Folia Phoniatrica et Logopaedica*, *59*(4), 165–170. <https://doi.org/10.1159/000102927>, PubMed: 17627124
- Desmond, J. E., Gabrieli, J. D., Wagner, A. D., Ginier, B. L., & Glover, G. H. (1997). Lobular patterns of cerebellar activation in verbal working-memory and finger-tapping tasks as revealed by functional MRI. *Journal of Neuroscience*, *17*(24), 9675–9685. <https://doi.org/10.1523/JNEUROSCI.17-24-09675.1997>, PubMed: 9391022
- Dice, L. R. (1945). Measures of the amount of ecologic association between species. *Ecology*, *26*(3), 297–302. <https://doi.org/10.2307/1932409>
- Dick, A. S., & Tremblay, P. (2012). Beyond the arcuate fasciculus: Consensus and controversy in the connectional anatomy of language. *Brain*, *135*(Part 12), 3529–3550. <https://doi.org/10.1093/brain/aww222>, PubMed: 23107648
- Diedrichsen, J., Balsters, J. H., Flavell, J., Cussans, E., & Ramnani, N. (2009). A probabilistic MR atlas of the human cerebellum. *NeuroImage*, *46*(1), 39–46. <https://doi.org/10.1016/j.neuroimage.2009.01.045>, PubMed: 19457380
- Diedrichsen, J., & Zotow, E. (2015). Surface-based display of volume-averaged cerebellar imaging data. *PLOS One*, *10*(7), Article e0133402. <https://doi.org/10.1371/journal.pone.0133402>, PubMed: 26230510
- Doyon, J., Laforce, R., Jr., Bouchard, G., Gaudreau, D., Roy, J., Poirier, M., Bédard, P. J., Bédard, F., & Bouchard, J. P. (1998). Role of the striatum, cerebellum and frontal lobes in the automatization of a repeated visuomotor sequence of movements. *Neuropsychologia*, *36*(7), 625–641. [https://doi.org/10.1016/S0028-3932\(97\)00168-1](https://doi.org/10.1016/S0028-3932(97)00168-1), PubMed: 9723934
- Duffau, H. (2015). Stimulation mapping of white matter tracts to study brain functional connectivity. *Nature Reviews Neurology*, *11*(5), 255–265. <https://doi.org/10.1038/nrneurol.2015.51>, PubMed: 25848923
- Dum, R. P., & Strick, P. L. (2003). An unfolded map of the cerebellar dentate nucleus and its projections to the cerebral cortex. *Journal of Neurophysiology*, *89* (1), 634–639. <https://doi.org/10.1152/jn.00626.2002>, PubMed: 12522208
- Elam, J. (2021). *HCP-YA Data Dictionary—Updated for the 1200 Subject Release* [Instrument worksheet]. HCP Wiki—Public Data. <https://wiki.humanconnectome.org/display/PublicData/HCP-YA+Data+Dictionary+-+Updated+for+the+1200+Subject+Release>



- Fabbro, F., Tavano, A., Corti, S., Bresolin, N., De Fabritiis, P., & Borgatti, R. (2004). Longterm neuropsychological deficits after cerebellar infarctions in two young twins. *Neuropsychologia*, 42(4), 536–545. <https://doi.org/10.1016/j.neuropsychologia.2003.09.006>, PubMed: 14728925
- Fedorov, A., Beichel, R., Kalpathy-Cramer, J., Finet, J., Fillion-Robin, J.-C., Pujol, S., Bauer, C., Jennings, D., Fennessy, F. M., Sonka, M., Buatti, J., Aylward, S. R., Miller, J. V., Pieper, S., & Kikinis, R. (2012). 3D slicer as an image computing platform for the quantitative imaging network. *Magnetic Resonance Imaging*, 30(9), 1323–1341. <https://doi.org/10.1016/j.mri.2012.05.001>, PubMed: 22770690
- Fengler, A., Meyer, L., & Friederici, A. D. (2016). How the brain attunes to sentence processing: Relating behavior, structure, and function. *NeuroImage*, 129, 268–278. <https://doi.org/10.1016/j.neuroimage.2016.01.012>, PubMed: 26777477
- Fiez, J. A. (2016). The cerebellum and language: Persistent themes and findings. *Brain and Language*, 161, 1–3. <https://doi.org/10.1016/j.bandl.2016.09.004>, PubMed: 27663062
- Fischer, M. H., & Zwaan, R. A. (2008). Embodied language: A review of the role of the motor system in language comprehension. *Quarterly Journal of Experimental Psychology*, 61(6), 825–850. <https://doi.org/10.1080/17470210701623605>, PubMed: 18470815
- Ford, A. A., Colon-Perez, L., Triplett, W. T., Gullett, J. M., Mareci, T. H., & FitzGerald, D. B. (2013). Imaging white matter in human brainstem. *Frontiers in Human Neuroscience*, 7, 400. <https://doi.org/10.3389/fnhum.2013.00400>, PubMed: 23898254
- Frazier, J. A., Chiu, S., Breeze, J. L., Makris, N., Lange, N., Kennedy, D. N., Herbert, M. R., Bent, E. K., Koneru, V. K., Dieterich, M. E., Hodge, S. M., Rauch, S. L., Grant, P. E., Cohen, B. M., Seidman, L. J., Caviness, V. S., & Biederman, J. (2005). Structural brain magnetic resonance imaging of limbic and thalamic volumes in pediatric bipolar disorder. *American Journal of Psychiatry*, 162(7), 1256–1265. <https://doi.org/10.1176/appi.ajp.162.7.1256>, PubMed: 15994707
- Friederici, A. D. (2002). Towards a neural basis of auditory sentence processing. *Trends in Cognitive Neuroscience*, 6(2), 78–84. [https://doi.org/10.1016/S1364-6613\(00\)01839-8](https://doi.org/10.1016/S1364-6613(00)01839-8), PubMed: 15866191
- Friederici, A. D., Opitz, B., & von Cramon, D. Y. (2000). Segregating semantic and syntactic aspects of processing in the human brain: An fMRI investigation of different word types. *Cerebral Cortex*, 10(7), 698–705. <https://doi.org/10.1093/cercor/10.7.698>, PubMed: 10906316
- Friederici, A. D., Rüschemeyer, S. A., Hahne, A., & Fiebach, C. J. (2003). The role of left inferior frontal and superior temporal cortex in sentence comprehension: Localizing syntactic and semantic processes. *Cerebral Cortex*, 13(2), 170–177. <https://doi.org/10.1093/cercor/13.2.170>, PubMed: 12507948
- Frost, J. A., Binder, J. R., Springer, J. A., Hammeke, T. A., Bellgowan, P. S. F., Rao, S. M., & Cox, R. W. (1999). Language processing is strongly left lateralized in both sexes: Evidence from functional MRI. *Brain*, 122(Part 2), 199–208. <https://doi.org/10.1093/brain/122.2.199>, PubMed: 10071049
- Gershon, R. C., Cook, K. F., Mungas, D., Manly, J. J., Slotkin, J., Beaumont, J. L., & Weintraub, S. (2014). Language measures of the NIH Toolbox Cognition Battery. *Journal of the International Neuropsychological Society*, 20(6), 642–651. <https://doi.org/10.1017/S1355617714000411>, PubMed: 24960128
- Gershon, R. C., Slotkin, J., Manly, J. J., Blitz, D. L., Beaumont, J. L., Schnipke, D., Wallner-Allen, K., Golinkoff, R. M., Gleason, J. B., Hirsh-Pasek, K., Adams, M. J., & Weintraub, S. (2013). NIH Toolbox Cognition Battery (CB): Measuring language (vocabulary comprehension and reading decoding). *Monographs of the Society for Research in Child Development*, 78(4), 49–69. <https://doi.org/10.1111/mono.12034>, PubMed: 23952202
- Geva, S., Schneider, L. M., Roberts, S., Green, D. W., & Price, C. J. (2021). The effect of focal damage to the right medial posterior cerebellum on word and sentence comprehension and production. *Frontiers in Human Neuroscience*, 15, Article 664650. <https://doi.org/10.3389/fnhum.2021.664650>, PubMed: 34093152
- Glasser, M. F., Sotiropoulos, S. N., Wilson, J. A., Coalson, T. S., Fischl, B., Andersson, J. L., Xu, J., Jbabdi, S., Webster, M., Polimeni, J. R., Van Essen, D. C., Jenkinson, M., & WU-Minn HCP Consortium. (2013). The minimal preprocessing pipelines for the human connectome project. *NeuroImage*, 80, 105–124. <https://doi.org/10.1016/j.neuroimage.2013.04.127>, PubMed: 23668970
- Glickstein, M., May, J. G., III, & Mercier, B. E. (1985). Corticopontine projection in the macaque: The distribution of labelled cortical cells after large injections of horseradish peroxidase in the pontine nuclei. *Journal of Comparative Neurology*, 235(3), 343–359. <https://doi.org/10.1002/cne.902350306>, PubMed: 3998215
- Goldstein, J. M., Seidman, L. J., Makris, N., Ahern, T., O'Brien, L. M., Caviness, V. S., Jr., Kennedy, D. N., Faraone, S. V., & Tsuang, M. T. (2007). Hypothalamic abnormalities in schizophrenia: Sex effects and genetic vulnerability. *Biological Psychiatry*, 61(8), 935–945. <https://doi.org/10.1016/j.biopsych.2006.06.027>, PubMed: 17046727
- Gonzalo-Ruiz, A., & Leichnetz, G. R. (1990). Connections of the caudal cerebellar interpositus complex in a new world monkey (*Cebus apella*). *Brain Research Bulletin*, 25(6), 919–927. [https://doi.org/10.1016/0361-9230\(90\)90189-7](https://doi.org/10.1016/0361-9230(90)90189-7), PubMed: 2289174
- Griffanti, L., Salimi-Khorshidi, G., Beckmann, C. F., Auerbach, E. J., Douaud, G., Sexton, C. E., Zsoldos, E., Ebmeier, K. P., Filippini, N., Mackay, C. E., Moeller, S., Xu, J., Yacoub, E., Baselli, G., Uğurbil, K., Miller, K. L., & Smith, S. M. (2014). ICA-based artefact removal and accelerated fMRI acquisition for improved resting state network imaging. *NeuroImage*, 95, 232–247. <https://doi.org/10.1016/j.neuroimage.2014.03.034>, PubMed: 24657355
- Guell, X., Gabrieli, J. D. E., & Schmahmann, J. D. (2018). Triple representation of language, working memory, social and emotion processing in the cerebellum: Convergent evidence from task and seed-based resting-state fMRI analyses in a single large cohort. *NeuroImage*, 172, 437–449. <https://doi.org/10.1016/j.neuroimage.2018.01.082>, PubMed: 29408539
- Guell, X., Schmahmann, J. D., & Gabrieli, J. D. E., & Ghosh, S. S. (2018). Functional gradients of the cerebellum. *eLife*, 7, Article e36652. <https://doi.org/10.7554/eLife.36652>, PubMed: 30106371
- Heleven, E., van Dun, K., De Witte, S., Baeken, C., & Van Overwalle, F. (2021). The role of the cerebellum in social and non-social action sequences: A preliminary LF-rTMS study. *Frontiers in Human Neuroscience*, 15, Article 593821. <https://doi.org/10.3389/fnhum.2021.593821>, PubMed: 33716690
- Hoche, F., Guell, X., Vangel, M. G., Sherman, J. C., & Schmahmann, J. D. (2018). The cerebellar cognitive affective/Schmahmann syndrome scale. *Brain*, 141(1), 248–270. <https://doi.org/10.1093/brain/awx317>, PubMed: 29206893
- Hua, K., Zhang, J., Wakana, S., Jiang, H., Li, X., Reich, D. S., Calabresi, P. A., Pekar, J. J., van Zijl, P. C. M., & Mori, S. (2008). Tract probability maps in stereotaxic spaces: Analyses of white matter anatomy and tract-specific quantification.



- NeuroImage*, 39(1), 336–347. <https://doi.org/10.1016/j.neuroimage.2007.07.053>, PubMed: 17931890
- Hull, C. (2020). Prediction signals in the cerebellum: Beyond supervised motor learning. *eLife*, 9, Article e54073. <https://doi.org/10.7554/eLife.54073>, PubMed: 32223891
- Ikuta, N., Sugiura, M., Sassa, Y., Watanabe, J., Akitsuki, Y., Iwata, K., Miura, N., Okamoto, H., Watanabe, Y., Sato, S., Horie, K., Matsue, Y., & Kawashima, R. (2006). Brain activation during the course of sentence comprehension. *Brain and Language*, 97(2), 154–161. <https://doi.org/10.1016/j.bandl.2005.10.006>, PubMed: 16298427
- Ito, H., Murakami, T., Fukuoka, T., & Kishida, R. (1986). Thalamic fiber connections in a teleost (*Sebastiscus marmoratus*): Visual somatosensory, octavolateral, and cerebellar relay region to the telencephalon. *Journal of Comparative Neurology*, 250(2), 215–227. <https://doi.org/10.1002/cne.902500208>, PubMed: 3745513
- Ito, M. (1984). *The cerebellum and neural control*. Raven Press.
- Ito, M. (2008). Control of mental activities by internal models in the cerebellum. *Nature Reviews Neuroscience*, 9(4), 304–313. <https://doi.org/10.1038/nrn2332>, PubMed: 18319727
- Ivry, R. B., & Keele, S. W. (1989). Timing functions of the cerebellum. *Journal of Cognitive Neuroscience*, 1(2), 136–152. <https://doi.org/10.1162/jocn.1989.1.2.136>, PubMed: 23968462
- Jenkinson, M., Beckmann, C. F., Behrens, T. E. J., Woolrich, M. W., & Smith, S. M. (2012). FSL. *NeuroImage*, 62, 782–790. <https://doi.org/10.1016/j.neuroimage.2011.09.015>, PubMed: 21979382
- Jissendi, P., Baudry, S., & Balériaux, D. (2008). Diffusion tensor imaging (DTI) and tractography of the cerebellar projections to prefrontal and posterior parietal cortices: A study at 3T. *Journal of Neuroradiology*, 35(1), 42–50. <https://doi.org/10.1016/j.neurad.2007.11.001>, PubMed: 18206240
- Jones, D. K. (2010). Challenges and limitations of quantifying brain connectivity in vivo with diffusion MRI. *Imaging in Medicine*, 2(3), 341–355. <https://doi.org/10.2217/iim.10.21>
- Jossinger, S., Kronfeld-Duenias, V., Zislis, A., Amir, O., & Ben-Shachar, M. (2021). Speech rate association with cerebellar white-matter diffusivity in adults with persistent developmental stuttering. *Brain Structure & Function*, 226(3), 801–816. <https://doi.org/10.1007/s00429-020-02210-7>, PubMed: 33538875
- Just, M. A., Carpenter, P. A., Keller, T. A., Eddy, W. F., & Thulborn, K. R. (1996). Brain activation modulated by sentence comprehension. *Science*, 274(5284), 114–116. <https://doi.org/10.1126/science.274.5284.114>, PubMed: 8810246
- Karavasilis, E., Christidi, F., Velonakis, G., Giavri, Z., Kelekis, N. L., Efstathopoulos, E. P., Evdokimidis, I., & Dellatolas, G. (2019). Ipsilateral and contralateral cerebello-cerebellar white matter connections: A diffusion tensor imaging study in healthy adults. *Journal of Neuroradiology*, 46(1), 52–60. <https://doi.org/10.1016/j.neurad.2018.07.004>, PubMed: 30098370
- Kawato, M., & Gomi, H. (1992). A computational model of four regions of the cerebellum based on feedback-error learning. *Biological Cybernetics*, 68(2), 95–103. <https://doi.org/10.1007/BF00201431>, PubMed: 1486143
- Keller, T. A., Carpenter, P. A., & Just, M. A. (2001). The neural bases of sentence comprehension: A fMRI examination of syntactic and lexical processing. *Cerebral Cortex*, 11(3), 223–237. <https://doi.org/10.1093/cercor/11.3.223>, PubMed: 11230094
- Kelly, R. M., & Strick, P. L. (2003). Cerebellar loops with motor cortex and prefrontal cortex of a nonhuman primate. *Journal of Neuroscience*, 23(23), 8432–8444. <https://doi.org/10.1523/JNEUROSCI.23-23-08432.2003>, PubMed: 12968006
- Keser, Z., Hasan, K. M., Mwangi, B. I., Kamali, A., Ucisik-Keser, F. E., Riascos, R. F., Yozbatiran, N., Francisco, G. E., & Narayana, P. A. (2015). Diffusion tensor imaging of the human cerebellar pathways and their interplay with cerebral macrostructure. *Frontiers in Neuroanatomy*, 9, 41. <https://doi.org/10.3389/fnana.2015.00041>, PubMed: 25904851
- Kieren, F. M., & Buckner, R. L. (2009). Segregated fronto-cerebellar circuits revealed by intrinsic functional connectivity. *Cerebral Cortex*, 19(10), 2485–2497. <https://doi.org/10.1093/cercor/bhp135>, PubMed: 19592571
- Kikinis, R., Pieper, S. D., & Vosburgh, K. (2014). 3D slicer: A platform for subject-specific image analysis, visualization, and clinical support. In F. Jolesz (Ed.), *Intraoperative imaging image-guided therapy* (pp. 277–289). Springer. [https://doi.org/10.1007/978-1-4614-7657-3\\_19](https://doi.org/10.1007/978-1-4614-7657-3_19)
- King, M., Hernandez-Castillo, C. R., Poldrack, R. A., Ivry, R. B., & Diedrichsen, J. (2019). Functional boundaries in the human cerebellum revealed by a multi-domain task battery. *Nature Neuroscience*, 22(8), 1371–1378. <https://doi.org/10.1038/s41593-019-0436-x>, PubMed: 31285616
- Krestel, H., Annoni, J.-M., & Jagella, C. (2013). White matter in aphasia: A historical review of Dejerines' studies. *Brain and Language*, 127(3), 526–532. <https://doi.org/10.1016/j.bandl.2013.05.019>, PubMed: 23895939
- LeBel, A., Jain, S., & Huth, A. G. (2021). Voxelwise encoding models show that cerebellar language representations are highly conceptual. *Journal of Neuroscience*, 41(50), 10341–10355. <https://doi.org/10.1523/JNEUROSCI.0118-21.2021>, PubMed: 34732520
- Lee, D.-H., Park, J. W., Park, S.-H., & Hong, C. (2015). Have you ever seen the impact of crossing fiber in DTI?: Demonstration of the corticospinal tract pathway. *PLOS One*, 10(7), Article e0112045. <https://doi.org/10.1371/journal.pone.0112045>, PubMed: 26135795
- Leggio, M., & Molinari, M. (2015). Cerebellar sequencing: A trick for predicting the future. *Cerebellum*, 14(1), 35–38. <https://doi.org/10.1007/s12311-014-0616-x>, PubMed: 25331541
- Leiner, H. C., Leiner, A. L., & Dow, R. S. (1993). Cognitive and language functions of the human cerebellum. *Trends in Neurosciences*, 16(11), 444–447. [https://doi.org/10.1016/0166-2236\(93\)90072-T](https://doi.org/10.1016/0166-2236(93)90072-T), PubMed: 7507614
- Maier-Hein, K. H., Neher, P. F., Houde, J.-C., Côté, M.-A., Garyfallidis, E., Zhong, J., Chamberland, M., Yeh, F.-C., Lin, Y.-C., Ji, Q., Reddick, W. E., Glass, J. O., Chen, D. Q., Feng, Y., Gao, C., Wu, Y., Ma, J., He, R., Li, Q., ... Descoteaux, M. (2017). The challenge of mapping the human connectome based on diffusion tractography. *Nature Communications*, 8(1), 1349. <https://doi.org/10.1038/s41467-017-01285-x>, PubMed: 29116093
- Makris, N., Goldstein, J. M., Kennedy, D., Hodge, S. M., Caviness, V. S., Faraone, S. V., Tsuang, M. T., & Seidman, L. J. (2006). Decreased volume of left and total anterior insular lobule in schizophrenia. *Schizophrenia Research*, 83(2–3), 155–171. <https://doi.org/10.1016/j.schres.2005.11.020>, PubMed: 16448806
- Malone, I. B., Leung, K. K., Clegg, S., Barnes, J., Whitwell, J. L., Ashburner, J., Fox, N. C., & Ridgway, G. R. (2015). Accurate automatic estimation of total intracranial volume: A nuisance variable with less nuisance. *NeuroImage*, 104, 366–372. <https://doi.org/10.1016/j.neuroimage.2014.09.034>, PubMed: 25255942
- Marek, S., Siegel, J. S., Gordon, E. M., Raut, R. V., Gratton, C., Newbold, D. J., Ortega, M., Laumann, T. O., Adeyemo, B., Miller, D. B., Zheng, A., Lopez, K. C., Berg, J. J., Coalson, R. S., Nguyen, A. L., Dierker, D., Van, A. N., Hoyt, C. R., McDermott, K. B., ... Dosenbach, N. U. F. (2018). Spatial and temporal organization of the individual human cerebellum.

- Neuron*, 100(4), 977–993. <https://doi.org/10.1016/j.neuron.2018.10.010>, PubMed: 30473014
- Mariën, P., Ackermann, H., Adamaszek, M., Barwood, C. H., Beaton, A., Desmond, J., De Witte, E., Fawcett, A. J., Hertrich, I., Küper, M., Leggio, M., Marvel, C., Molinari, M., Murdoch, B. E., Nicolson, R. I., Schmahmann, J. D., Stoodley, C. J., Thürling, M., Timmann, D., Wouters, E., & Ziegler, W. (2014). Consensus paper: Language and the cerebellum: An ongoing enigma. *Cerebellum*, 13(3), 386–410. <https://doi.org/10.1007/s12311-013-0540-5>, PubMed: 24318484
- Mariën, P., & Borgatti, R. (2018). Language and the cerebellum. In *Handbook of clinical neurology* (Vol. 154, pp. 181–202). <https://doi.org/10.1016/B978-0-444-63956-1.00011-4>, PubMed: 29903439
- Mariën, P., Engelborghs S., Fabbro F., & De Deyn P. P. (2001). The lateralized linguistic cerebellum: A review and a new hypothesis. *Brain and Language*, 79(3), 580–600. <https://doi.org/10.1006/brln.2001.2569>, PubMed: 11781058
- Mariën, P., Engelborghs, S., Pickut, B. A., & De Deyn, P. P. (2000). Aphasia following cerebellar damage: Fact or fallacy? *Journal of Neurolinguistics*, 13(2–3), 145–171. [https://doi.org/10.1016/S0911-6044\(00\)00009-9](https://doi.org/10.1016/S0911-6044(00)00009-9)
- Marvel, C. L., & Desmond, J. E. (2010). Functional topography of the cerebellum in verbal working memory. *Neuropsychology Review*, 20(3), 271–279. <https://doi.org/10.1007/s11065-010-9137-7>, PubMed: 20563894
- Mesulam, M.-M., Thompson, C. K., Weintraub, S., & Rogalski, E. J. (2015). The Wernicke conundrum and the anatomy of language comprehension in primary progressive aphasia. *Brain*, 138(8), 2423–2437. <https://doi.org/10.1093/brain/awv154>, PubMed: 26112340
- Metoki, A., Wang, Y., & Olson, I. R. (2021). The social cerebellum: A large-scale investigation of functional and structural specificity and connectivity. *Cerebral Cortex*, 32(5), 987–1003. <https://doi.org/10.1093/cercor/bhab260>, PubMed: 34428293
- Middlebrooks, E. H., Yagmurlu, K., Szaflarski, J. P., Rahman, M., & Bozkurt, B. (2017). A contemporary framework of language processing in the human brain in the context of preoperative and intraoperative language mapping. *Neuroradiology*, 59(1), 69–87. <https://doi.org/10.1007/s00234-016-1772-0>, PubMed: 28005160
- Middleton, F. A., & Strick, P. L. (1997). Cerebellar output channels. *International Review of Neurobiology*, 41, 61–82. [https://doi.org/10.1016/S0074-7742\(08\)60347-5](https://doi.org/10.1016/S0074-7742(08)60347-5), PubMed: 9378611
- Mirailié, C. (1896). *De l'aphasie sensorielle*. G. Steinheil.
- Moberget, T., & Ivry, R. B. (2016). Cerebellar contributions to motor control and language comprehension: Searching for common computational principles. *Annals of the New York Academy of Sciences*, 1369(1), 154–171. <https://doi.org/10.1111/nyas.13094>, PubMed: 27206249
- Molinari, M., Leggio, M. G., Solida, A., Ciorra, R., Misciagna, S., Silveri, M. C., & Petrosini, L. (1997). Cerebellum and procedural learning: Evidence from focal cerebellar lesions. *Brain*, 120(10), 1753–1762. <https://doi.org/10.1093/brain/120.10.1753>, PubMed: 9365368
- Mori, S., Wakana, S., Nagae-Poetscher, L. M., & van Zijl, P. C. M. (2005). *MRI atlas of human white matter* (1st ed.). Springer. <https://doi.org/10.1016/B978-044451741-8/50001-9>
- Murdoch, B. E., & Whelan, B.-M. (2007). Language disorders subsequent to left cerebellar lesions: A case for bilateral cerebellar involvement in language? *Folia Phoniatrica et Logopaedica*, 59(4), 184–189. <https://doi.org/10.1159/000102930>, PubMed: 17627127
- Oldfield, R. C. (1971). The assessment and analysis of handedness: The Edinburgh Inventory. *Neuropsychologia*, 9(1), 97–113. [https://doi.org/10.1016/0028-3932\(71\)90067-4](https://doi.org/10.1016/0028-3932(71)90067-4), PubMed: 5146491
- Palesi, F., De Rinaldis, A., Castellazzi, G., Calamante, F., Muhlert, N., Chard, D., Tournier, J. D., Magenes, G., D'Angelo, E., & Wheeler-Kingshott, C. A. M. G. (2017). Contralateral cortico-ponto-cerebellar pathways reconstruction in humans in vivo: Implications for reciprocal cerebro-cerebellar structural connectivity in motor and non-motor areas. *Science Reports*, 7(1), Article 12841. <https://doi.org/10.1038/s41598-017-13079-8>, PubMed: 28993670
- Palesi, F., Ferrante, M., Gaviraghi, M., Misiti, A., Savini, G., Lasciari, A., D'Angelo, E., & Wheeler-Kingshott, C. A. M. G. (2021). Motor and higher-order functions topography of the human dentate nuclei identified. *Human Brain Mapping*, 42(13), 4348–4361. <https://doi.org/10.1002/hbm.25551>, PubMed: 34087040
- Palesi, F., Tournier, J.-D., Calamante, F., Muhlert, N., Castellazzi, G., Chard, D., D'Angelo, E., & Wheeler-Kingshott, C. A. M. G. (2015). Contralateral cerebello-thalamo-cortical pathways with prominent involvement of associative areas in humans in vivo. *Brain Structure and Function*, 220(6), 3369–3384. <https://doi.org/10.1007/s00429-014-0861-2>, PubMed: 25134682
- Peterburs, J., Liang, Y., Cheng, D. T., & Desmond, J. E. (2021). Sensory acquisition functions of the cerebellum in verbal working memory. *Brain Structure and Function*, 226(3), 833–844. <https://doi.org/10.1007/s00429-020-02212-5>, PubMed: 33481104
- Pu, M., Heleven, E., Delplanque, J., Gibert, N., Ma, Q., Funghi, G., & Van Overwalle, F. (2020). The posterior cerebellum supports the explicit sequence learning linked to trait attribution. *Cognitive Affective & Behavioral Neuroscience*, 20(4), 798–815. <https://doi.org/10.3758/s13415-020-00803-7>, PubMed: 32495270
- Ramnani, N. (2014). Automatic and controlled processing in the corticocerebellar system. *Progress in Brain Research*, 210, 255–285. <https://doi.org/10.1016/B978-0-444-63356-9.00010-8>, PubMed: 24916296
- Ramnani, N. (2006). The primate cortico-cerebellar system: Anatomy and function. *Nature Reviews Neuroscience*, 7(7), 511–522. <https://doi.org/10.1038/nrn1953>, PubMed: 16791141
- Ramnani, N. (2012). Frontal lobe and posterior parietal contributions to the cortico-cerebellar system. *Cerebellum*, 11(2), 366–383. <https://doi.org/10.1007/s12311-011-0272-3>, PubMed: 21671065
- Raymond, J. L., & Medina, J. F. (2018). Computational principles of supervised learning in the cerebellum. *Annual Review of Neuroscience*, 41, 233–253. <https://doi.org/10.1146/annurev-neuro-080317-061948>, PubMed: 29986160
- Reveley, C., Seth, A. K., Pierpaoli, C., Silva, A. C., Yu, D., Saunders, R. C., Leopold, D. A., & Ye, F. Q. (2015). Superficial white matter fiber systems impede detection of long-range cortical connections in diffusion MR tractography. *Proceedings of the National Academy of Sciences*, 112(21), E2820–E2828. <https://doi.org/10.1073/pnas.1418198112>, PubMed: 25964365
- Riedel, M. C., Ray, K. L., Dick, A. S., Sutherland, M. T., Hernandez, Z., Fox, P. M., Eickhoff, S. B., Fox, P. T., & Laird, A. R. (2015). Meta-analytic connectivity and behavioral parcellation of the human cerebellum. *NeuroImage*, 117, 327–342. <https://doi.org/10.1016/j.neuroimage.2015.05.008>, PubMed: 25998956
- Rogalsky, C., Matchin, W., & Hickok, G. (2008). Broca's area, sentence comprehension, and working memory: An fMRI study.

- Frontiers in Human Neuroscience*, 2, 14. <https://doi.org/10.3389/neuro.09.014.2008>, PubMed: 18958214
- Salman, M. S. (2002). The cerebellum: It's about time! But timing is not everything: New insights into the role of the cerebellum in timing motor and cognitive tasks. *Journal of Child Neurology*, 17(1), 1–9. <https://doi.org/10.1177/088307380201700101>, PubMed: 11913561
- Salmi, J., Pallesen, K. J., Neuvonen, T., Brattico, E., Korvenoja, A., Salonen, O., & Carlson, S. (2010). Cognitive and motor loops of the human cerebro-cerebellar system. *Journal of Cognitive Neuroscience*, 22(11), 2663–2676. <https://doi.org/10.1162/jocn.2009.21382>, PubMed: 19925191
- Schilling, K. G., Petit, L., Rheault, F., Remedios, S., Pierpaoli, C., Anderson, A. W., Landman, B. A., & Descoteaux, M. (2020). Brain connections derived from diffusion MRI tractography can be highly anatomically accurate—If we know where white matter pathways start, where they end, and where they do not go. *Brain Structure and Function*, 225(8), 2387–2420. <https://doi.org/10.1007/s00429-020-02129-z>, PubMed: 32816112
- Schmahmann, J. D. (1996). From movement to thought: Anatomic substrates of the cerebellar contribution to cognitive processing. *Human Brain Mapping*, 4(3), 174–198. [https://doi.org/10.1002/\(SICI\)1097-0193\(1996\)4:3<174::AID-HBM3>3.0.CO;2-0](https://doi.org/10.1002/(SICI)1097-0193(1996)4:3<174::AID-HBM3>3.0.CO;2-0), PubMed: 20408197
- Schmahmann, J. D., & Pandya, D. N. (1991). Projections to the basis pontis from the superior temporal sulcus and superior temporal region in the rhesus monkey. *Journal of Comparative Neurology*, 308(2), 224–248. <https://doi.org/10.1002/cne.903080209>, PubMed: 1716269
- Schmahmann, J. D., & Pandya, D. N. (1997). The cerebrocerebellar system. *International Review of Neurobiology*, 41, 31–60. [https://doi.org/10.1016/S0074-7742\(08\)60346-3](https://doi.org/10.1016/S0074-7742(08)60346-3), PubMed: 9378595
- Schmahmann, J. D., & Sherman, J. C. (1998). The cerebellar cognitive affective syndrome. *Brain*, 121(Part 4), 561–579. <https://doi.org/10.1093/brain/121.4.561>, PubMed: 9577385
- Schwartz, M., & Kotz, S. A. (2016). Contributions of cerebellar event-based temporal processing and preparatory function to speech perception. *Brain and Language*, 161, 28–32. <https://doi.org/10.1016/j.bandl.2015.08.005>, PubMed: 26362972
- Silveri, M. C. (2021). Contribution of the cerebellum and the basal ganglia to language production: Speech, word fluency, and sentence construction—evidence from pathology. *Cerebellum*, 20(2), 282–294. <https://doi.org/10.1007/s12311-020-01207-6>, PubMed: 33120434
- Silveri, M. C., Leggio, M. G., & Molinari, M. (1994). The cerebellum contributes to linguistic production: A case of agrammatical speech following a right cerebellar lesion. *Neurology*, 44(11), 2047–2050. <https://doi.org/10.1212/WNL.44.11.2047>, PubMed: 7969957
- Smith, S. M., Vidaurre, D., Beckmann, C. F., Glasser, M. F., Jenkinson, M., Miller, K. L., Nichols, T. E., Robinson, E. C., Salimi-Khorshidi, G., Woolrich, M. W., Barch, D. M., Uğurbil, K., & Van Essen, D. C. (2013). Functional connectomics from resting-state fMRI. *Trends in Cognitive Sciences*, 17(12), 666–682. <https://doi.org/10.1016/j.tics.2013.09.016>, PubMed: 24238796
- Smits, M., Jiskoot, L. C., & Papma, J. M. (2014). White matter tracts of speech and language. *Seminars in Ultrasound, CT, and MR*, 35(5), 504–516. <https://doi.org/10.1053/j.sult.2014.06.008>, PubMed: 25217302
- Sokolov, A. A., Erb, M., Grodd, W., & Pavlova, M. A. (2014). Structural loop between the cerebellum and the superior temporal sulcus: Evidence from diffusion tensor imaging. *Cerebral Cortex*, 24(3), 626–632. <https://doi.org/10.1093/cercor/bhs346>, PubMed: 23169930
- Sørensen, T. (1948). A method of establishing groups of equal amplitude in plant sociology based on similarity of species content and its application to analyses of the vegetation on Danish commons. *Biologiske Skrifter/Kongelige Danske Videnskabernes Selskab*, 5, 1–34.
- Sotiropoulos, A. N., Jbabdi, S., Xu, J., Andersson, J. L., Moeller, S., Aurbach, E. J., Glasser, M. F., Hernandez, M., Sapiro, G., Jenkinson, M., Feinberg, A., Yacoub, E., Lenglet, C., Van Essen, D. C., Uğurbil, K., & Behrens, T. E. J. (2013). Advances in diffusion MRI acquisition and processing in the Human Connectome Project. *NeuroImage*, 80, 125–143. <https://doi.org/10.1016/j.neuroimage.2013.05.057>, PubMed: 23702418
- Spencer, K. A., & Slocumb, D. L. (2007). The neural basis of ataxic dysarthria. *Cerebellum*, 6(1), 58–65. <https://doi.org/10.1080/14734220601145459>, PubMed: 17366266
- Steele, C. J., Anwender, A., Bazin, P.-L., Trampel, R., Schaefer, A., Turner, R., Ramnani, N., & Villringer, A. (2017). Human cerebellar sub-millimeter diffusion imaging reveals the motor and non-motor topography of the dentate nucleus. *Cerebral Cortex*, 27(9), 4537–4548. <https://doi.org/10.1093/cercor/bhw258>, PubMed: 27600851
- Stoodley, C. J., & Tsai, P. T. (2021). Adaptive prediction for social contexts: The cerebellar contribution to typical and atypical social behaviors. *Annual Review of Neuroscience*, 44, 475–493. <https://doi.org/10.1146/annurev-neuro-100120-092143>, PubMed: 34236892
- Strick, P. L., Dum, R. P., & Fiez, J. A. (2009). Cerebellum and non-motor function. *Annual Review of Neuroscience*, 32, 413–434. <https://doi.org/10.1146/annurev-neuro.31.060407.125606>, PubMed: 19555291
- Takaya, S., Kuperberg, G. R., Liu, H., Greve, D. N., Makris, N., & Stufflebeam, S. M. (2015). Asymmetric projections of the arcuate fasciculus to the temporal cortex underlie lateralized language function in the human brain. *Frontiers in Neuroanatomy*, 9, 119. <https://doi.org/10.3389/fnana.2015.00119>, PubMed: 26441551
- Taoka, T., Kin, T., Nakagawa, H., Hirano, M., Sakamoto, M., Wada, T., Takayama, K., Wuttikul, C., Iwasaki, S., Ueno, S., & Kichikawa, K. (2007). Diffusivity and diffusion anisotropy of cerebellar peduncles in cases of spinocerebellar degenerative disease. *NeuroImage*, 37(2), 387–393. <https://doi.org/10.1016/j.neuroimage.2007.05.028>, PubMed: 17583535
- Thomas, C., Ye, F. Q., Irfanoglu, M. O., Modi, P., Saleem, K. S., Leopold, D. A., & Pierpaoli, C. (2014). Anatomical accuracy of brain connections derived from diffusion MRI tractography is inherently limited. *Proceedings of the National Academy of Sciences*, 111(46), 16574–16579. <https://doi.org/10.1073/pnas.1405672111>, PubMed: 25368179
- Tournier, J. D., Calamante, F., & Connelly, A. (2012). MRtrix: Diffusion tractography in crossing fiber regions. *International Journal of Imaging Systems and Technology*, 22(1), 53–66. <https://doi.org/10.1002/ima.22005>.
- Tournier, J.-D., Yeh, C.-H., Calamante, F., Cho, K.-H., Connelly, A., & Lin, C.-O. (2008). Resolving crossing fibres using constrained spherical deconvolution: Validation using diffusion-weighted imaging phantom data. *NeuroImage*, 42(2), 617–625. <https://doi.org/10.1016/j.neuroimage.2008.05.002>, PubMed: 18583153
- Tremblay, P., & Dick, A. S. (2016). Broca and Wernicke are dead, or moving past the classic model of language neurobiology. *Brain and Language*, 162, 60–71. <https://doi.org/10.1016/j.bandl.2016.08.004>, PubMed: 27584714



- Turken, A. U., & Dronkers, N. F. (2011). The neural architecture of the language comprehension network: Converging evidence from lesion and connectivity analyses. *Frontiers in Systems Neuroscience*, *5*, 1. <https://doi.org/10.3389/fnsys.2011.00001>, PubMed: 21347218
- Van Essen, D. C., Uğurbil, K., Auerbach, E., Barch, D., Behrens, T. E. J., Bucholz, R., Chang, A., Chen, L., Corbetta, M., Curtiss, S. W., Della Penna, S., Feinberg, D., Glasser, N. H., Herath, A. C., Larson-Prior, L., Marcus, D., Michalareas, G., Moeller, S., Oostenveld, R., ... WU-Minn HCP Consortium. (2012). The Human Connectome Project: A data acquisition perspective. *NeuroImage*, *62*(4), 2222–2231. <https://doi.org/10.1016/j.neuroimage.2012.02.018>, PubMed: 22366334
- Van Ettinger-Veenstra, H., McAllister, A., Lundberg, P., Karlsson, T., & Engström, M. (2016). Higher language ability is related to angular gyrus activation increase during semantic processing, independent of sentence incongruency. *Frontiers in Human Neuroscience*, *10*, 110. <https://doi.org/10.3389/fnhum.2016.00110>, PubMed: 27014040
- Van Overwalle, F., Ma, Q., & Heleven, E. (2020). The posterior crus II cerebellum is specialized for social mentalizing and emotional self-experiences: A meta-analysis. *Social Cognitive and Affective Neuroscience*, *15*(9), 905–928. <https://doi.org/10.1093/scan/nsaa124>, PubMed: 32888303
- Van Overwalle, F., Manto, M., Cattaneo, Z., Clausi, S., Ferrari, C., Gabrieli, J. D. E., Guell, X., Heleven, E., Lupo, M., Ma, Q., Michelutti, M., Olivito, G., Pu, M., Rice, L. C., Schmahmann, J. D., Siciliano, L., Sokolov, A. A., Stoodley, C. J., van Dun, K., Vandervert, L., & Leggio, M. (2020). Consensus paper: Cerebellum and social cognition. *Cerebellum*, *19*(6), 833–868. <https://doi.org/10.1007/s12311-020-01155-1>, PubMed: 32632709
- Van Overwalle, F., Manto, M., Leggio, M., & Delgado-García, J. M. (2019). The sequencing process generated by the cerebellum crucially contributes to social interactions. *Medical Hypotheses*, *128*, 33–42. <https://doi.org/10.1016/j.mehy.2019.05.014>, PubMed: 31203906
- Van Overwalle, F., Pu, M., Ma, Q., Li, M., Haihambo, N., Baetens, K., Deroost, N., Baeken, C., & Heleven, E. (2021). The involvement of the posterior cerebellum in reconstructing and predicting social action sequences. *Cerebellum*, *21*(5), 733–741. <https://doi.org/10.1007/s12311-021-01333-9>, PubMed: 34694590
- Vias, C., & Dick, A. S. (2017). Cerebellar contributions to language in typical and atypical development: A review. *Developmental Neuropsychology*, *42*(6), 404–421. <https://doi.org/10.1080/87565641.2017.1334783>, PubMed: 28885046
- Vicari, S., Piccini, G., Mercuri, E., Battini, R., Chieffo, D., Bulgheroni, S., Pecini, C., Lucibello, S., Lenzi, S., Moriconi, F., Pane, M., D'Amico, A., Astrea, G., Baranello, G., Riva, D., Cioni, G., & Alfieri, P. (2018). Implicit learning deficit in children with Duchenne muscular dystrophy: Evidence for a cerebellar cognitive impairment? *PLOS One*, *13*(1), Article e0191164. <https://doi.org/10.1371/journal.pone.0191164>, PubMed: 29338029
- Voevodskaya, O., Simmons, A., Nordenskjöld, R., Kullberg, J., Ahlström, H., Lind, L., Wahlund, L.-O., Larsson, E.-M., Westman, E., & Alzheimer's Disease Neuroimaging Initiative. (2014). The effects of intracranial volume adjustment approaches on multiple regional MRI volumes in healthy aging and Alzheimer's disease. *Frontiers in Aging Neuroscience*, *6*, 264. <https://doi.org/10.3389/fnagi.2014.00264>, PubMed: 25339897
- Wakana, S., Caprihan, A., Panzenboeck, M. M., Fallon, J. H., Perry, M., Gollub, R. L., Hua, K., Zhang, J., Jiang, H., Dubey, P., Blitz, A., van Zijl, P., & Mori, S. (2007). Reproducibility of quantitative tractography methods applied to cerebral white matter. *NeuroImage*, *36*(3), 630–644. <https://doi.org/10.1016/j.neuroimage.2007.02.049>, PubMed: 17481925
- Wang, F., Sun, Z., Du, X., Wang, X., Cong, Z., Zhang, H., Zhang, D., & Hong, D. (2003). A diffusion tensor imaging study of middle and superior cerebellar peduncle in male patients with schizophrenia. *Neuroscience Letters*, *348*(3), 135–138. [https://doi.org/10.1016/S0304-3940\(03\)00589-5](https://doi.org/10.1016/S0304-3940(03)00589-5), PubMed: 12932812
- Wolpert, D. M., Miall, R. C., & Kawato, M. (1998). Internal models in the cerebellum. *Trends in Cognitive Sciences*, *2*(9), 338–347. [https://doi.org/10.1016/S1364-6613\(98\)01221-2](https://doi.org/10.1016/S1364-6613(98)01221-2), PubMed: 21227230
- WU-Minn HCP Consortium. (2015). Appendix I – Protocol guidance and HCP session protocols. In *WU-Minn HCP 900 subjects data release: Reference manual* (pp. 1–55). WU-Minn Consortium of the Human Connectome Project. [https://www.humanconnectome.org/storage/app/media/documentation/s900/HCP\\_S900\\_Release\\_Appendix\\_I.pdf](https://www.humanconnectome.org/storage/app/media/documentation/s900/HCP_S900_Release_Appendix_I.pdf)
- Yang, Z., Wu, P., Weng, X., & Bandettini, P. A. (2014). Cerebellum engages in automation of verb-generation skill. *Journal of Integrative Neuroscience*, *13*(1), 1–17. <https://doi.org/10.1142/S0219635214500010>, PubMed: 24738536
- Yarkoni, T., Poldrack, R., Nichols, T., Van Essen, D., & Wager, T. (2011, September 4–6). NeuroSynth: A new platform for large-scale automated synthesis of human functional neuroimaging data [Poster presentation]. 4th INCF Congress of Neuroinformatics, Boston, MA.